

## **Comparative Analysis of Skin Treatment Methods after Laser Tattoo Removal**

**Ozodov Jasur Hamzayevich**

Bukhara State Medical Institute, Department Dermatovenereology

**Annotation:** This study focuses on a comparative analysis of skin treatment methods following laser tattoo removal. The research investigates the morphometric parameters of the skin in white outbred rats after the removal of tattoos, and compares the effectiveness of two treatments: dexpanthenol-containing ointment (Bepanten®) and pomegranate seed oil. The results show that pomegranate seed oil is more effective in promoting skin healing due to its rich composition of acids, vitamins, and antioxidants. This oil provides anti-inflammatory, anti-tumor, and antioxidant benefits, contributing to faster recovery of the skin. The study provides valuable insights into the potential of pomegranate seed oil as an alternative treatment method for post-tattoo removal care.

**Keywords:** laser tattoo removal, skin treatment, dexpanthenol, pomegranate seed oil, morphometric analysis, epidermis, antioxidants, inflammation reduction, healing process, rats

### **INTRODUCTION**

In recent years, tattoos have become a popular form of self-expression among people worldwide, with millions of individuals opting for body art. However, the removal of tattoos, particularly through laser treatment, can lead to skin damage, requiring proper aftercare to ensure healing. This study aims to compare the effectiveness of two skin treatment methods—dexpanthenol-containing ointment and pomegranate seed oil—following laser tattoo removal. By analyzing the morphometric changes in the skin of rats, the research seeks to identify the most efficient treatment for promoting skin recovery and minimizing complications.

Relevance: recent years, there has been an increased interest among young people in tattoos. About 100 million Europeans have tattoos, i.e. 10-20% of the adult population, and it's time to pay attention to tattooed skin and health. Tattoos have not lost their relevance in our time: applying both black and white and color images to the skin is a fashion trend and a way of self-expression among people around the world.

According to statistics from various studies, about 4% of people who get a tattoo suffer from pain for a month afterward, and 22% suffer from itching, which lasts more than 4-5 weeks. 3% contract some kind of infection while getting a tattoo. A survey of students showed that 17% of tattoo owners did not get them done in a salon, and 21% of respondents said that they were drunk at the time the design was applied to their skin. Getting a tattoo involves a large amount of tattoo ink being injected into the skin.

Tattoo dyes usually contain various substances, the main ingredient of which is a coloring component, which can be classified into two different groups. First, amorphous carbon particles (soot) are found almost exclusively in black tattoos. Secondly, tattoo artists use azo and polycyclic pigments to create almost all colors of the visible spectrum. Because of their varied

but often complex chemistry, tattoo dyes typically contain various compounds, such as byproducts and impurities that can cause health problems. Professional tattoo artists inject this mixture into the skin using solid tattoo machine needles.

The purpose of the study: study of morphometric parameters of the skin during skin treatment after laser tattoo removal.

**MATERIALS AND METHODS OF RESEARCH:** to conduct an experimental study, 150 white outbred rats of both sexes, weighing 200-250 grams, were selected under standard vivarium conditions. These laboratory animals received from the nursery were subjected to a mandatory veterinary examination to identify existing diseases, assess their condition and age. Accepted animals were quarantined for 21 days to prevent the introduction of infectious diseases into the vivarium.

All groups were formed at the same time. The laboratory animals participating in the experiment were representative in age, sex, weight, housing and feeding conditions. After 30 days of feeding, groups of laboratory animals were humanely killed and necropsies were performed. When killing and dissecting laboratory animals, biological safety rules and ethical principles for working with laboratory animals were observed. When working with laboratory animals, all rules of biological safety and ethical principles of working with laboratory animals given in the methodological manual Nuralieva N.A., Bektimirova A.M., Alimova M.G., Suvanova K.Zh. will be observed. "Rules and methods of working with laboratory animals in microbiological and immunological research", approved by M3 of the Republic of Uzbekistan on May 25, 2016.

To apply the tattoo, we used a convenient and modern tool, which is now at the peak of popularity - the Cheyenne Hawk Thunder Black tattoo pen, made in Germany.

To apply the tattoo, we used ink from the most famous manufacturer - the American company World Famous Tattoo Ink (WFTI), which produces high-quality blue pigment.

Morphological changes in the skin of white outbred rats were identified, the results were recorded in journals, the results were statistically processed and described in the form of a research report.

In order to conduct a comparative analysis of the morphological changes in the skin of the base of the tail of white mongrel rats after tattoo removal, they were divided into two groups depending on the drug used to treat the removed tattoo site:

Group I - 55 white outbred rats, for skin treatment, which were treated with dexpanthenol containing ointment - Bepanten® (Germany) 0.5 g, 2 times a day every 12 hours for 14 days.

Group II - 55 white outbred rats, for skin treatment, which were treated with pomegranate seed oil 2 times a day, every 12 hours for 14 days.

Statistical processing of the obtained results was carried out using the methods of variation statistics using the application package Statistica for Windows. Digital data was processed on a personal computer using the memory of Microsoft Excell application programs. Information was considered reliable if  $t \geq 2$  and  $p < 0.05$ .

Results and discussions: as we can see from the histological picture, after removal of the tattoo at the base of the tail of white laboratory rats, thinning of the epidermal layer, swelling of the dermal layer, and hypodermis and hair follicles showed no changes.

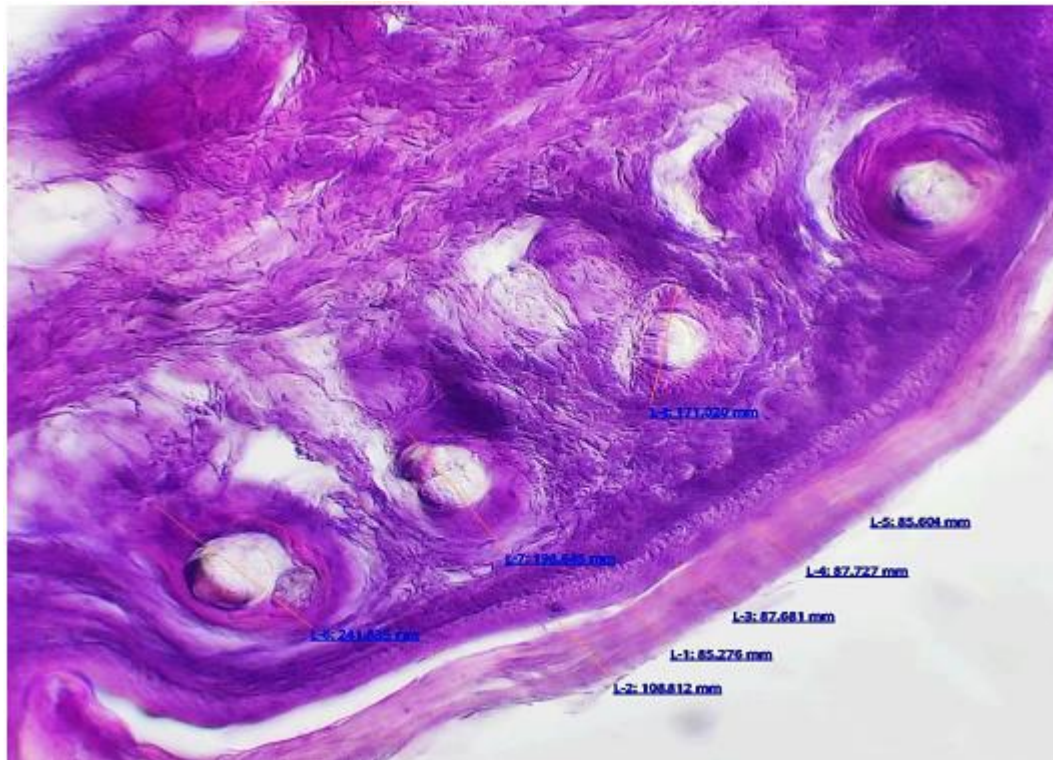


Fig.1. Skin of white mongrel rats after tattoo removal To determine the parameters of the structural parts of the skin in white outbred rats after laser tattoo removal, a morphometric analysis was carried out, the data of which are shown in table 1.

Table 1. Morphometric indicators of skin after tattoo removal

	Skin structure (μm)		
	Epidermis	Dermis	Hair follicle
After tattoo removal	132.78±13.03	224.69 ± 0.33	203.8±20.6

Morphometric analysis of the skin of white outbred rats after tattoo removal showed that the thickness of the epidermis varies from 85.3 to 182.8 microns, with an average of 132.78 microns, the thickness of the dermis from 223.12 to 226.21 microns, with an average of 224. 69 microns. When measuring the thickness of hair follicles, the following values were revealed: from 171 to 241.8 microns, with an average of 203.8 microns.

For a comparative analysis of skin parameters after treatment of a remote area with dexpanthenol containing ointment, a morphometric study was also carried out. (table 2.)

## RESULTS AND DISCUSSION

The histological analysis of the skin after tattoo removal showed significant changes, including thinning of the epidermal layer and swelling of the dermal layer, while hair follicles remained unaffected. Morphometric analysis revealed the thickness of the epidermis, dermis, and hair follicles post-removal. The treatment with pomegranate seed oil demonstrated superior effectiveness compared to dexpanthenol-containing ointment. Pomegranate seed oil, rich in essential fatty acids, vitamins, and antioxidants, contributed to faster reduction in swelling and provided stronger anti-inflammatory effects. Its high antioxidant content, including anthocyanins and ellagic acid, played a key role in skin recovery and protection from further damage. These findings suggest that pomegranate seed oil is a more efficient treatment for skin healing after laser tattoo removal.

## CONCLUSION

It follows that the use of pomegranate seed oil when treating the skin after tattoo removal is a more effective method than dexpanthenol containing ointments, since pomegranate seed oil

contains many acids, such as linoleic, stearic, palmitic and oleic acids, and a large amount of vitamin E, in high concentrations of vitamins A, C and K. Linoleic acid is an important component of cell membranes and provides skin turgor; due to these properties, swelling is quickly relieved, and punic acid has antiinflammatory, antitumor and antioxidant properties. The high antioxidant property is due to anthacyans, tannins and ellagic acid. Along with the above, the oil also contains calcium, magnesium, potassium and selenium, as well as tocopherols, beta-sitosterols, stigmasterols and campesterols.

#### **References:**

1. Ozodov J. H. MORPHOLOGICAL ANALYSIS OF HUMAN SKIN AND THE SKIN OF TAIL IN MICE //International Bulletin of Applied Science and Technology. - 2022. - Vol. 2. - no. 11. - pp.166-175.
2. Ozodov J. H. MORPHOLOGICAL ANALYSIS OF HUMAN SKIN AND THE SKIN OF TAIL IN MICE //International Bulletin of Applied Science and Technology. - 2022. - Vol. 2. - no. 11. - pp. 166-175.
3. Ozodov J. H. BUXORO VILOYATIDA 2019-2022 YILLARDA LEYSHMANIOZ KASALLIGINING KLINIK SHAKLLARI UCHRASH DARAJASI TUMANLAR KESIMIDA //RESEARCH AND EDUCATION. – 2022. – T. 1. – №. 9. – C. 428-436.
4. Ozodov J. H. et al. EARLY EFFECTS OF TATTOOING ON MOUSE SKIN MORPHOLOGY AND MAIN DIFFERENTIAL FEATURES WITH NORMAL SKIN //International Journal of Medical Sciences And Clinical Research. – 2022. – T. 2. – №. 11. – C. 47-57.