

Survey on the Prevalence of Diabetes Mellitus (DM) Among Residents of Gashua Metropolis, Bade Local Government Area, Yobe State, Northeast, Nigeria

Mukhamadov N. A.

Department of Neurosurgery of the Multidisciplinary Clinic of Samarkand State Medical
University, Samarkand State Medical University

Abstract: The frequency of occurrence of variants of the development of the structure of cerebral vessels in patients with Kimmerle anomaly was studied. 67 patients with Kimmerle anomaly were examined, aged from 16 to 60 years, average age 40 ± 5 years; 55 women – 82.0% and 12 men – 18%. All subjects underwent MSCT of the brain with capture and 3D craniovertebral junction and MR angiography. Correlative data of radiological and clinical signs were determined with subsequent statistical processing. It has been determined that in most cases with Kimmerle's anomaly there are anomalies in the development of cerebral vessels.

Keywords: craniovertebral junction, MSCT, Kimmerle anomaly, MR angiography, cerebral vessels.

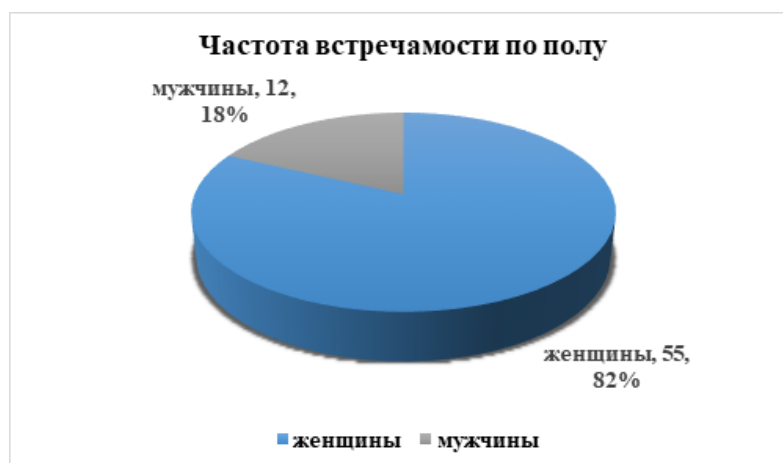Relevance. Changes in the craniovertebral junction are quite diverse, which causes the heterogeneity of clinical manifestations and, as a consequence, the extreme difficulty of identifying specific clinical syndromes [8]. Anomalies of spinal development have a significant impact on the statics and movement of the spine as a whole and in each spinal motion segment. A special place among various craniovertebral anomalies (KVA) is occupied by Kimmerle's anomaly (AK), characterized by changes in the area of the posterior arch of the atlas, ossification of the oblique atlanto-occipital ligament passing over the vertebral groove of the atlas, while a bone bridge is formed, turning the groove of the vertebral artery into a vaulted foramen [9]. The frequency of this anomaly is significant and amounts to about 15% of the world's population, as a congenital malformation, and can also be acquired during life, mainly as a result of dystrophic diseases of the spine [1]. The main pathogenic factors in the development of clinical symptoms in patients with Kimmerle anomaly are: extravasal compression of the vertebral artery, prolonged trauma to the vascular adventitia, as well as irritation of the paravascular sympathetic nerves and branches of the occipital nerve. Clinical symptoms of Kimmerle's anomaly are variable: headache, dizziness, tinnitus, transient hearing and vision disturbances, fatigue, sleep disturbances, unsteady gait, falling attacks, panic attacks, anxiety or asthma, numbness of the hands and seizures. Such patients often receive ineffective symptomatic therapy for a long time if timely visualization of the craniovertebral region (using CT) is not carried out [14].

Purpose of the study: To analyze the frequency of occurrence, clinical features and significance of diagnostic research methods for Kimmerle's anomaly among patients who are registered on an outpatient and inpatient basis in the neurosurgery department of the multidisciplinary clinic of SamSMU and compile their statistical data.

Materials and methods: The results of a survey of 67 patients (of which 55 women - 82.0% and 12 men - 18%) with diagnosed Kimmerle anomaly for 2020-2022 were used (Fig. 1). Exclusion criteria included severe somatic, mental pathology, and consequences of severe injuries to the spine and skull. Based on the medical history and clinical neurological examination, the results obtained by radiological diagnostics (X-ray), Doppler ultrasound, MR angiography and multislice computed tomography (MSCT) with 3-D reconstruction of the craniocervical junction were analyzed. The pain scale (VAS) was used to assess the neurological condition. The severity of the disease was assessed by 3 points. Depending on the intensity of clinical symptoms, as well as taking into account the modified Rankin scale (mRs) and Rivermead Mobility Index (Rmi):

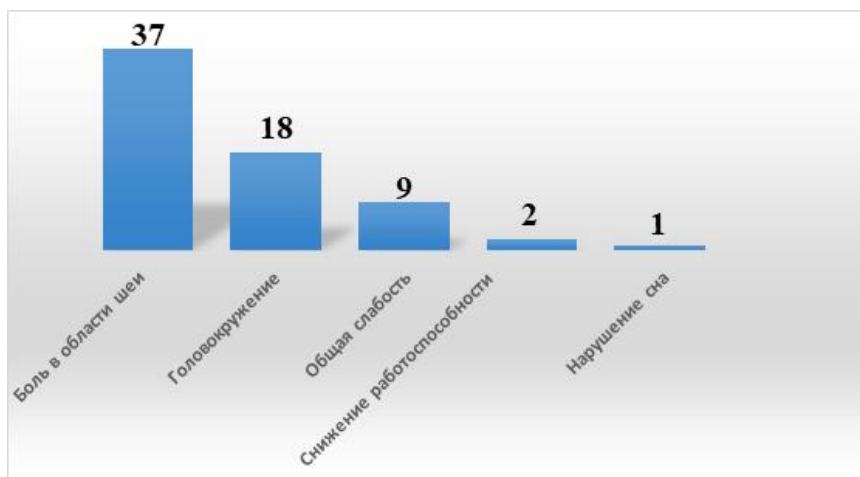
- Grade III: severe; presence of most clinical symptoms; patients are on bed rest for most of the day; acute attack of the clinical manifestation of the disease when rotating the head; mRs score ≥ 3 ; Rmi ≤ 7 .
- Grade II: Moderate severity; present with headache and vertebrobasilar insufficiency several times a year, which increases after turning the head at the onset of the disease; score mRs=1; Rmi=8-13.
- Grade I: Mild; the appearance of complaints during light physical activity; mRs score = 1; Rmi=14-15.

The obtained data were subjected to statistical processing.



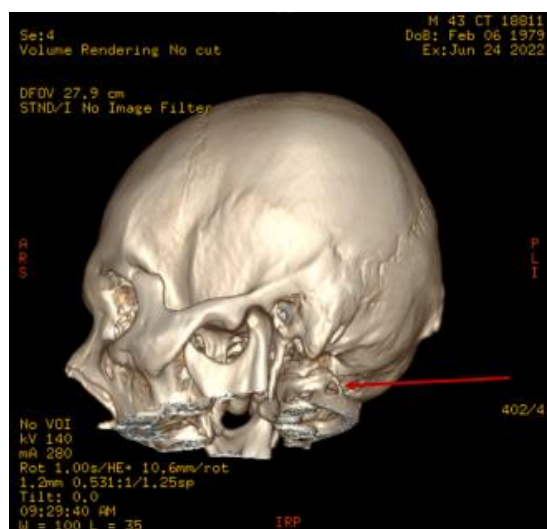
Rice. 1. Prevalence rate by gender.

Research results: According to clinical and neurological data, the examined patients complained of pain in the neck area - 37 (55.2%), moderate non-systemic dizziness - 18 (26.8%), general weakness and fatigue - 9 (13.4%), severe decreased performance – 2 (2.9%), sleep disturbance in 1 (1.5%) (Fig. 2).

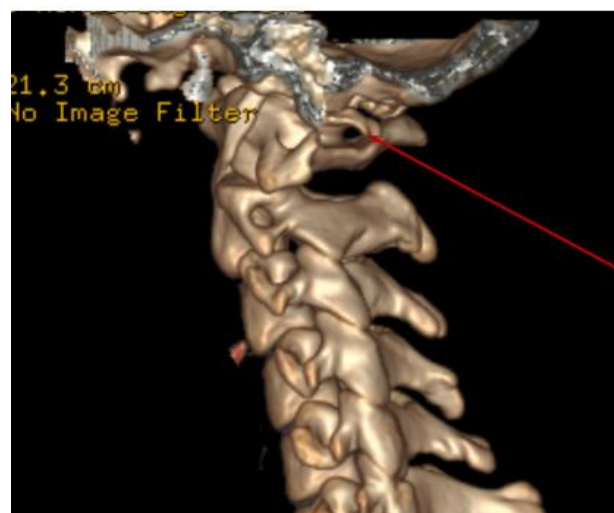


Rice. 2. Neurological symptoms found in patients with AK.

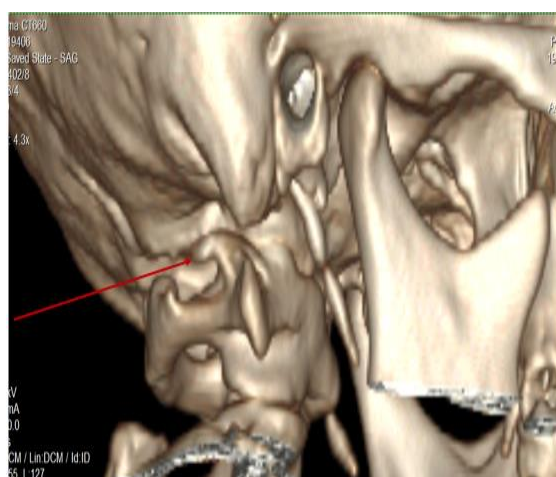
MSCT revealed the following forms of AK: unfused ring (n=45; 67.1%); unfused arches (n = 17; 25.3%); unfused bone bridge - (n=5; 7.5%) cases. According to the type, 51 (76.1%) patients had unilateral and 16 (23.8%) patients had bilateral Kimmerle anomaly. Of the unilateral anomalies on the right side in 22 (43%) patients, on the left side in 29 (56.8%) patients. Depending on the leading clinical sign, four main symptom complexes were identified: the syndrome of paroxysmal circulatory disorders in the vertebral arteries (25%) ($mRs \geq 3$; $Rmi \leq 7$), which was based on vestibulocerebellar, vestibulocochlear, oculocephalgic disorders and panic attacks; cephalgic syndrome (35%), vertebrobasilar syndrome (dizziness, nausea, tinnitus) (30%) ($mRs = 1$; $Rmi = 8-13$), radicular syndrome, which manifested itself as sharp pain in the form of lumbago in the neck with irradiation to the back of the head, inner ear, back wall of the pharynx, leading to a forced positional position of the head (10%) ($mRs = 1$; $Rmi = 14-15$).



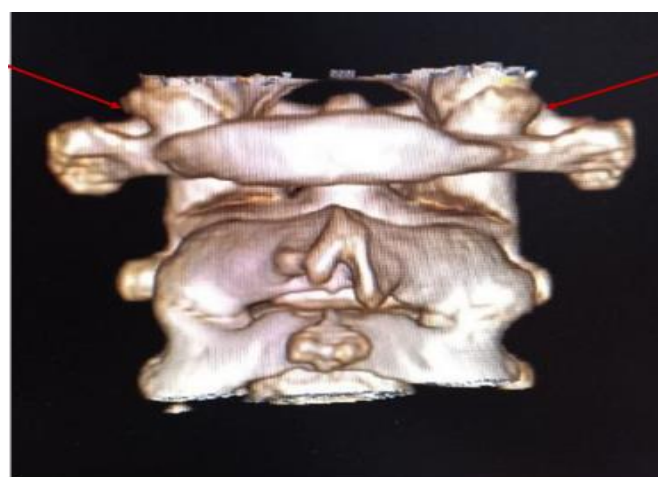
A. Unfused bone ring on the left.



B. Incomplete bone ring



C. Incomplete bone ring.



D. Incomplete bone bridge on both sides.

Rice. 2. MSCT of the craniovertebral junction with 3D reconstruction of bone structures. Various types of Kimmerle Anomaly.

To determine the structure of the vessels of the arterial circle of the cerebrum and the structural features of the main arteries of the head in patients with craniovertebral anomaly, 100% of patients underwent MR angiography of the vessels of the neck and head (MRA). The types of development of cerebral vessels were determined according to Lelyuk V.G., Lelyuk S.E., (2003) (Fig. 3). In 38 (56.7%) patients, unilateral hypoplasia of the vertebral artery was determined, aplasia of the vertebral artery was detected in 1 (1.5%). An open circle of Willis of various types was visualized in 59 (59.7%) patients. In 36 (53.7%) patients with Kimmerle's Anomaly (AK), the absence of posterior communicating arteries was detected, of which in 21 (31.3%) both

posterior communicating arteries (PCA) were not visualized, in 15 (22.4%) - one ZSA. The absence of posterior communicating arteries in combination with hypoplasia of the vertebral artery was detected in 28 (41.8%) patients. In 11 (16.4%) patients with AK, posterior trifurcation was detected - the origin of the posterior cerebral artery from the internal carotid artery: in 1 - left-sided posterior trifurcation, in 8 - right-sided and in 1 - bilateral posterior trifurcation. In the control group, posterior trifurcation occurred in 6% of cases. According to literature data, posterior trifurcation of the internal carotid artery (ICA) is detected in 10-15% of cases, without predominance on a particular side. According to the results of MR A, tortuosity of the main arteries of the head (MAG) was to a greater extent represented in the vessels of the vertebrobasilar region. Most often, in 23 (34.3%) patients, tortuosity of the vertebral artery (VA) was determined predominantly with the formation of bends along arcs of medium and small radius of segments V3-V4. In the control group, tortuosity (TA) was detected in 4 (6.7%) patients, segment V2. Arcuate tortuosity of the basilar artery – in 27 (27.6%), in 11 cases it was combined with VA hypoplasia. In the control group, no tortuosity of the basilar artery was noted. ICA tortuosity was detected in 19 (28.6%) patients; in 17.3% of cases it was combined with vascular tortuosity in the vertebrobasilar region (VBB). In 8 (11.9%) patients, a combination of variants in the structure of the arterial circle of the cerebrum of the cerebrum ACBM and MAG was noted. In the control group, ICA tortuosity was determined in isolation in 9 (13.4%) cases, without combination with variants of ACBM. Thus, analysis of MRA results in 96% of patients with AK confirmed the presence of variants in the structure of cerebral vessels, which are signs of impaired formation and development of MAG. MR data in 65 (97%) patients with AK indicated the presence of structural signs of impaired intracranial venous circulation. There was a decrease in blood flow through the superior sagittal sinus in 37 (46.3%) patients.

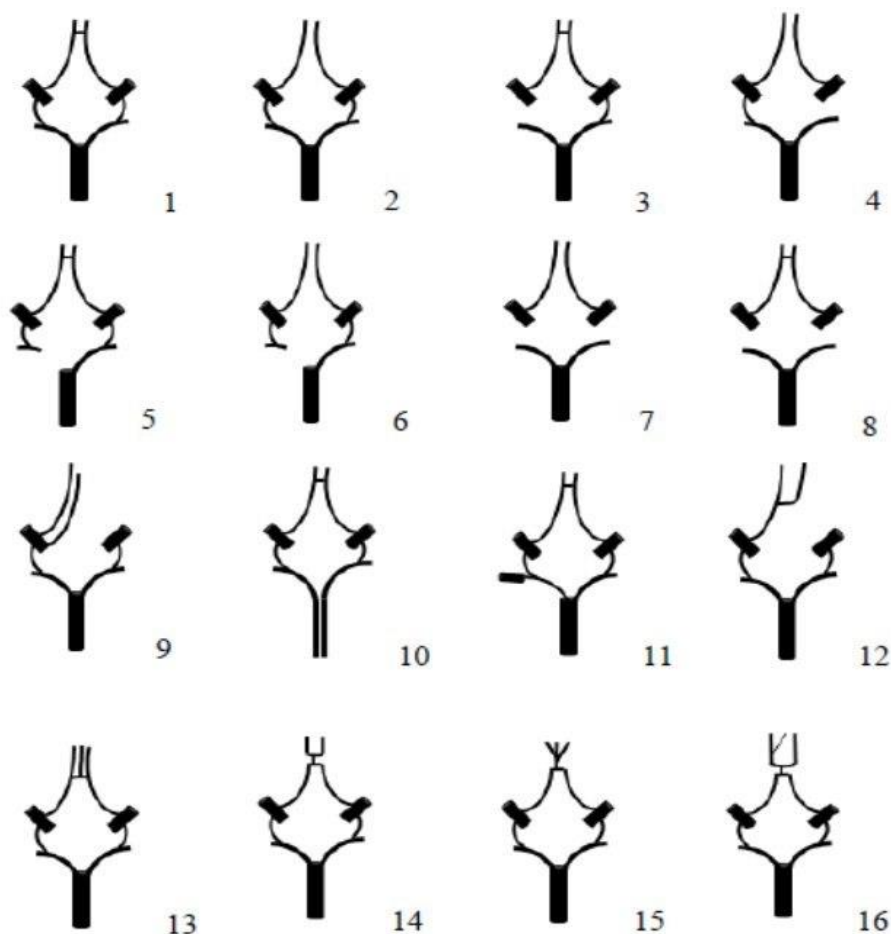


Fig 3.

Anomalies in the development of cerebral arteries (according to Lelyuk V.G., Lelyuk S.E., 2003 and Niederberger E., et.al., 2010, as amended) [5, 19]. 1 – “classic” type, 2 – absence of anterior communicating branch, 3 – absence of one posterior communicating branch, 4 – absence of anterior and one posterior communicating artery, 5 – posterior trifurcation (the origin of the posterior cerebral artery from the internal carotid), 6 – posterior trifurcation with the simultaneous absence of the anterior communicating artery, 7 - absence of all communicating arteries, 8 - absence of both posterior communicating arteries, 9 - anterior trifurcation (the origin of both anterior cerebral arteries from the internal carotid artery of one side), 10 - absence of the basilar artery, 11 - posterior hypoplasia cerebral artery, 12 - incomplete duplication of the anterior cerebral artery, 13 - accessory (third) anterior cerebral artery, 14 - single trunk of the anterior cerebral artery, 15 - unpaired anterior cerebral artery, 16 - bihemispheric anterior cerebral artery.

Below are the types of anatomical structure of intracranial vessels in patients with AK admitted to the neurosurgery department of the Samara State Medical University multidisciplinary hospital.

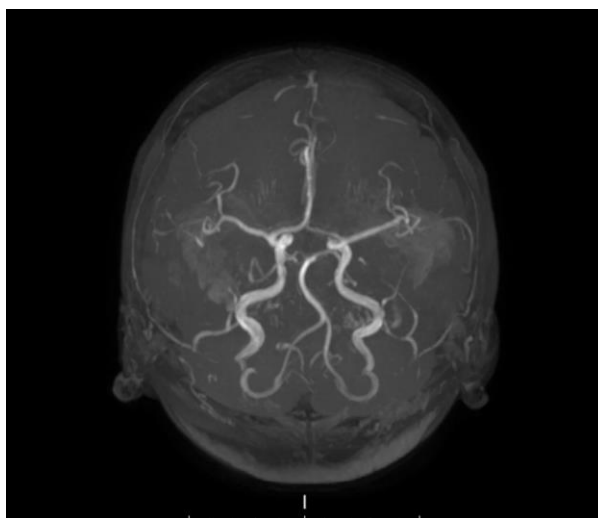


Fig.4.Posterior trifurcation of the siphon of the right ICA (severe hypoplasia of the P1 segment of the right PCA, compensatory blood flow through the hyperplastic right PCA).

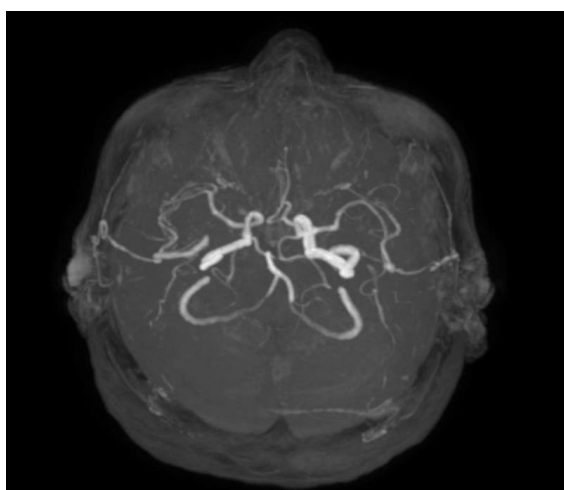


Fig.5.Anterior trifurcation of the siphon of the left ICA (severe hypoplasia of the A1 segment of the right ACA, compensatory blood flow through the hyperplastic ACA). Posterior trifurcation of the siphon of the left ICA (severe hypoplasia of the P1 segment of the left PCA, compensatory blood flow through the hyperplastic left PCA).

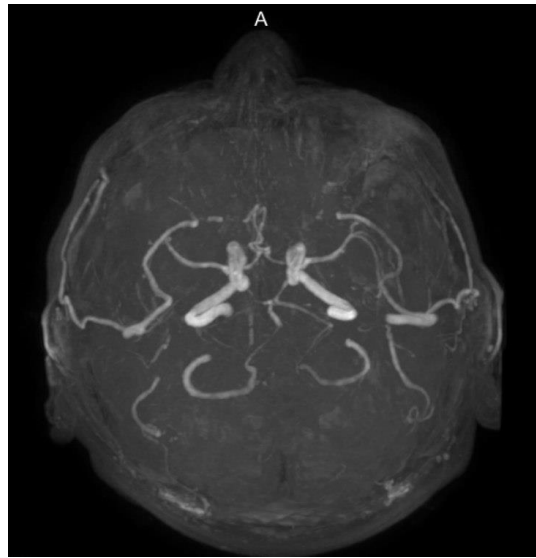


Fig.6.Severe tortuosity and hypoplasia of the ICA and VA on both sides.

Hypoplasia of the anterior sections of the superior sagittal sinus (in 6 cases - aplasia of the anterior sections) was combined with the presence of pronounced anastomoses with the veins of the scalp and enrichment of blood flow through the basal veins. In the control group, hypoplasia of the superior sagittal sinus was detected in 16.7% of cases, and in no study were they noted to have enriched blood flow through the basal veins. A characteristic sign of impaired venous outflow from the cranial cavity was the MR venographic picture of asymmetry of the venous sinuses of the posterior cranial fossa (PCF). Hypoplasia of the transverse sinus in 48 (60%) patients was combined with an enrichment of the venous pattern of the posterior sinus, the formation of additional anastomoses with the veins of the soft tissues of the neck, internal vertebral veins and intradural veins. In the control group, hypoplasia of the transverse sinuses accounted for 6.7% of cases.

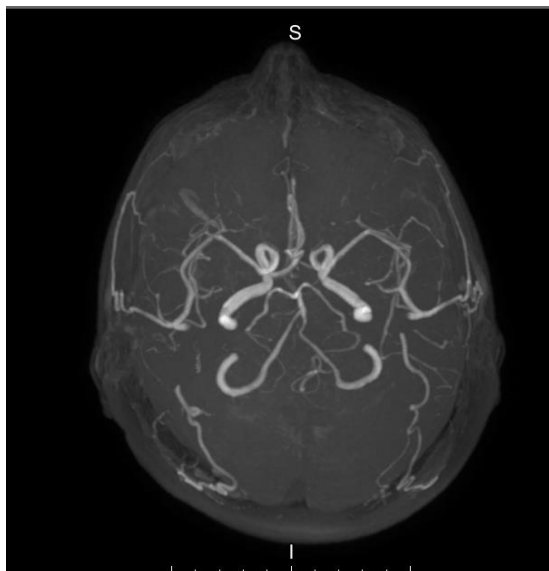

Fig. 12.Aplasia of the PCA on both sides

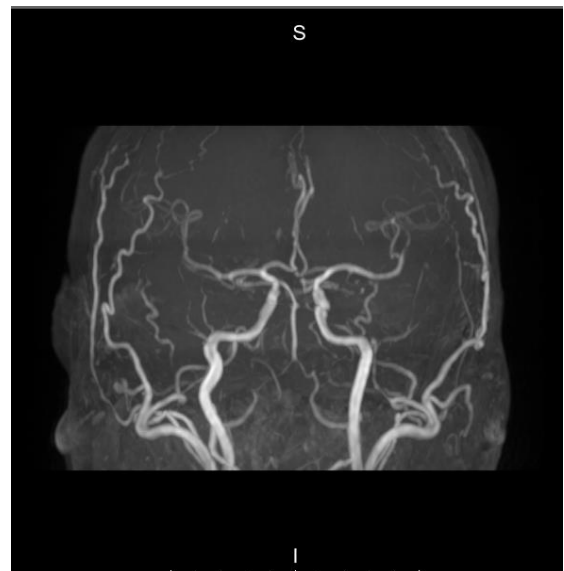


Fig.13Aplasia of the PCA on the left, hypoplasia on the right of the left VA

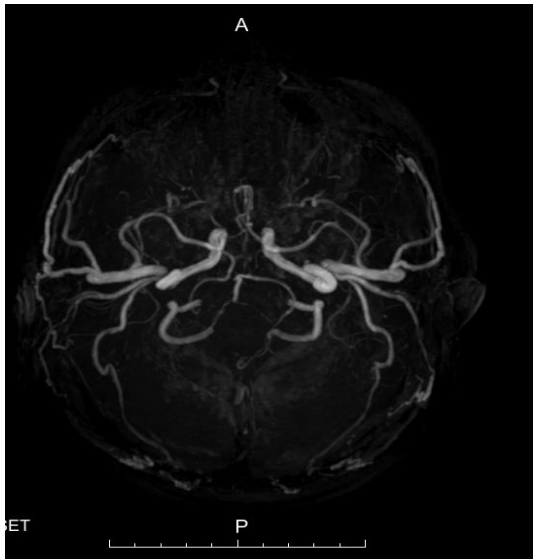


Fig. 14. Aplasia of the left VA, PCA.

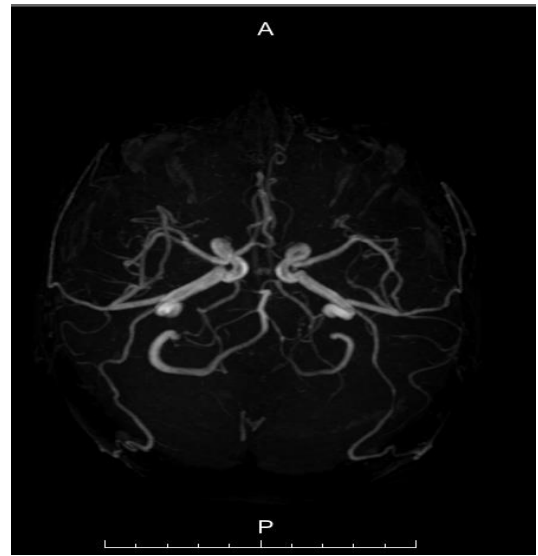


Fig. 15. Aplasia of the left ACA. ZSA on the right.

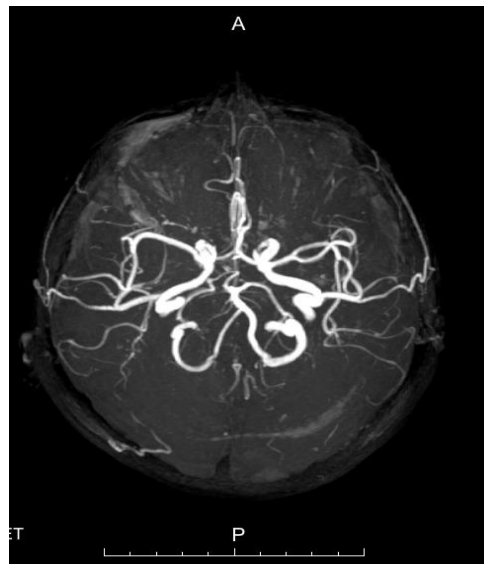


Fig.16 Excessive tortuosity of intracranial vessels.

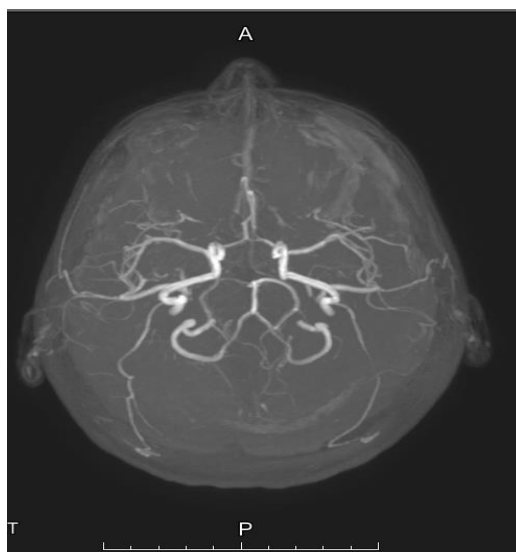

Fig.17 Hypoplasia of the right PCA

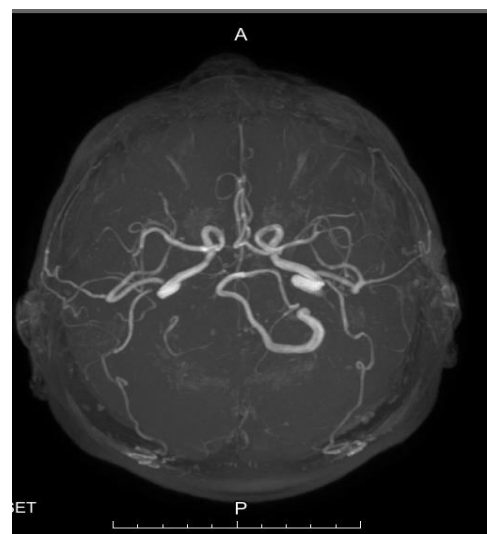


Fig. 18. Aplasia of the right VA, deformation of the basilar artery (BA), compensatory blood flow through the PCA on the left.

Conclusion: Thus, despite the relatively lower frequency of occurrence of Kimmerle's Anomaly, it represents many symptom complexes that need to be differentiated from other pathologies of the spine and head, which requires timely detection of the pathology using modern diagnostic methods. Kimmerle's anomaly is combined with variants of angiodysplasia of the arterial circle of the cerebrum, the main arteries of the head and the intracranial venous system. A comparison of clinical examination data and the results of assessing the hemodynamics of intracranial arterial and venous circulation in patients with Kimmerle anomaly confirms the significance of vascular changes in the pathogenesis of headache. Features of cerebral hemodynamics in patients with Kimmerle anomaly determine treatment and prevention tactics. Data from diagnostic and clinical neurological information are important in determining treatment tactics, in particular the choice of conservative or surgical treatment for patients with this pathology.

List of used literature.

1. Split W., Sawrasewicz-Rybak M. Clinical symptoms and signs in Kimmerle anomaly // Wiad. Lek. -2002. - Vol.55, N 7-8. - R. 416-421.
2. Kuć J, Szarejko KD, Aleksandrowicz K, Gołębowska M. The role of soft tissue mobilization in reducing orofacial and general complaints in a patient with Kimmerle anomaly and temporomandibular joint disorder: A case report. *Cranio*. 2021 Jan;39(1):74-87. doi: 10.1080/08869634.2018.1560616. Epub 2019 Jan 4. PMID: 30609909.
3. Koutsouraki E, Avdelidi E, Michmizos D, Kapsali SE, Costa V, Baloyannis S. Kimmerle's anomaly as a possible causative factor of chronic tension-type headaches and neurosensory hearing loss: case report and literature review. *Int J Neurosci*. 2010 Mar;120(3):236-9. doi: 10.3109/00207451003597193. PMID: 20374094.
4. Split W, Sawrasewicz-Rybak M. Character of headache in Kimmerle anomaly. *Headache*. 2002 Oct;42(9):911-6. doi: 10.1046/j.1526-4610.2002.02213.x. PMID: 12390620.
5. VP Selivanov, ZL Brodskaya. Kimmerle's anomaly and its clinical significance // *Orthopedics, traumatology and prosthetics*. 1973. No. 8. S.70-72
6. Koutsouraki E, Avdelidi E, Michmizos D, Kapsali SE, Costa V, Baloyannis S. Kimmerle's anomaly as a possible causative factor of chronic tension-type headaches and neurosensory hearing loss: case report and literature review. *Int J Neurosci*. 2010 Mar;120(3):236-9. doi: 10.3109/00207451003597193. PMID: 20374094.
7. Lvov I, Lukianchikov V, Grin A, Sytnik A, Polunina N, Krylov V. Minimally invasive surgical treatment for Kimmerle anomaly. *J Craniovert Jun Spine* 2017;8:359-63.
8. Development, anomalies and variant anatomy cerebral arteries
E. V. Chaplygina, O. A. Kaplunova, V. I. Dombrovsky, O. P. Sukhanova, I. M. Blinov, L. I. Chistolina. *Journal of Anatomy and Histopathology*. – 2015. – T. 4, No. 2. pp. 53-59.
9. Lachkepiani AN, Kurdiukova-Akhvlediani LS. Distsirkulatornye narusheniia v vertebral'no-baziliarnoi sisteme pri nalichii anomalii Kimmerle [Circulatory disorders in the vertebrobasilar system in the presence of Kimmerle's anomaly]. *Zh Nevropatol Psikiatr Im SS Korsakova*. 1990;90(1):23-6. Russian. PMID: 2158719.
10. Wang WH, Liu ZY, Guo HC, Wang H. Multiple Fractures of Cervical Vertebrae Combined with Arcuate Foramen and Vertebral Artery Occlusion: A Case Report and Literature Review. *Orthop Surg*. 2021 Feb;13(1):360-365. doi: 10.1111/os.12868. Epub 2020 Dec 3. PMID: 33274600; PMCID: PMC7862144.
11. NVA, Avinash M, KSS, Shetty AP, Kanna RM, Rajasekaran S. Congenital Osseous Anomalies of the Cervical Spine: Occurrence, Morphological Characteristics, Embryological

Basis and Clinical Significance: A Computed Tomography Based Study. *Asian Spine J.* 2019 Mar 14;13(4):535-543. doi: 10.31616/asj.2018.0260. PMID: 30866614; PMCID: PMC6680038.

12. Natsis K, Piperaki ET, Fratzoglou M, Lazaridis N, Tsitsopoulos PP, Samolis A, Kostares M, Piagkou M. Atlas posterior arch and vertebral artery's groove variants: a classification, morphometric study, clinical and surgical implications. *Surg Radiol Anat.* 2019 Sep;41(9):985-1001. doi:10.1007/s00276-019-02256-1. Epub 2019 Jun 6. PMID: 31172259.
13. Abtahi AM, Brodke DS, Lawrence BD. Vertebral artery anomalies at the craniovertebral junction: a case report and review of the literature. *Evid Based Spine Care J* 2014;5:121–125. DOI: 10.1055/s-0034-1386751.
14. Noh Y, Kwon OK, Kim HJ, Kim JS. Rotational vertebral artery syndrome due to compression of nondominant vertebral artery terminating in posterior inferior cerebellar artery. *J Neurol.* 2011;258:1775–1780. DOI: 10.1007/s00415-011-6005-1.
15. Bogorodinsky D.K. Craniovertebral pathology. M.: GEOTAR-Media, 2008. 631 p.
16. Gulyaev S.A., Kulagin V.N., Archipenko I.V., Gulyaeva S.E. Clinical manifestations of anomalies of the craniovertebral region according to the Kimmerle variant and features of their treatment // *Breast Cancer.* – 2013. – Volume 21, No. 16. – P. 866-868.
17. Komyakhov A.V. Diagnosis, treatment and prevention of neurological disorders in patients with Kimmerle anomaly: Author. Diss... cand. honey. Sci. – St. Petersburg, 2011.
18. Bahtadze MA Rol' anomalii Kimmerle v razvitii kompressionnyh sindromov pozvonochnoj arterii: Avtoref. diss... kand. med. nauk. – Moscow, 2002
19. Guljaev SA, Kulagin VN, Arhipenko IV, Guljaeva SE Klinicheskie projavlenija anomalii kraniovertebral'noj oblasti po variantu Kimmerle i osobennosti ih lechenija // *RMZh.* – 2013. – Volume 21, No. 16. – S. 866-868.
20. Komjahov AV Diagnostika, treatment i profilaktika nevrologicheskikh ras-strojstv u pacientov s anomaliej Kimmerle: Avtor. Diss...kand. med. nauk. – SPetersburg, 2011.
21. Kulagin VN, Mihajljukova SS, Lantuh AV, Balaba Ja.V., Matochkina AS, Popova AA Anomalija Kimmerle: aspekty diagnostiki i lechenija osnovnyh klinicheskikh sindromov // *Tihookeanskij medicinskij zhurnal.* – 2013. – No. 4. – S. 84-87.