

SURGICAL TREATMENT OF MENINGIOMA OF THE ANTERIOR CRANIAL FOSSA OF THE CRANIUM

Ravshanov Davron Mavlonovich.

Assistant at the Department of Neurosurgery, Samarkand State Medical University.
Samarkand. Uzbekistan

Abstract

Meningiomas are extracerebral, from the pia mater of the brain and spinal cord, and the choroid plexuses of the cerebral ventricles or arising ectopically in the bones of the skull, spine and along the nerve roots of the tumor. Meningiomas account for approximately one third of all intracranial tumors..

Keywords: description of successful surgical treatment of meningioma of the anterior cranial fossa

Introduction

Meningiomas are extracerebral, from the pia mater of the brain and spinal cord, and the choroid plexuses of the cerebral ventricles or arising ectopically in the bones of the skull, spine and along the nerve roots of the tumor. Meningiomas account for approximately one third of all intracranial tumors. The incidence of meningiomas is 6.58 per 100,000 population per year. This indicator increases with age, which, given the aging population of developed countries, further increases the significance of the problem. In people aged 35 years and older, meningioma is the most common tumor of the central nervous system. The current prevalence of meningiomas is 97.5 per 100,000 population.

Materials and methods Patient A., 53 years old, was admitted to the Department of Neurosurgery of the Multidisciplinary Clinic of Samarkand State Medical University. with complaints of general weakness, periodic severe headache, blurred vision.

An MRI of the brain revealed a meningioma at the base of the anterior cranial fossa and surgical treatment was recommended: craniotomy, removal of a space-occupying lesion in the anterior cranial fossa. Magnetic resonance imaging with contrast enhancement was performed: the resulting images revealed a round-shaped tumor formation in the anterior cranial fossa with clear, even contours of an isointense MR signal, measuring up to 5x4x5 cm, intensively accumulating a contrast agent. The tumor matrix is clearly visualized. There is compression of the substance of the frontal lobes with signs of perifocal edema up to 2.2 cm. The grooves are smoothed, the anterior horns of the lateral ventricles are compressed. Signs of growth in the third ventricle of the brain. The tumor is adjacent to the anterior cerebral arteries, the supraclinoid part of the internal carotid arteries. Upon admission, the general condition was moderate. Somatically compensated.

Consciousness is clear. There are no cerebral or meningeal symptoms. The sense of smell is lost on both sides. Decreased visual acuity, loss of visual fields. The range of movements of the eyeballs is full. There is no doubling. The pupils are uniform, measuring 3 mm. The reaction of the pupils on 2 sides, Visual acuity OD and OS was 0.02. Surgical treatment was performed using the “keyhole” technique, which is a modification of the standard approach, reducing the size of the skin incision and the size of the craniotomy.

Surgery of the base of the anterior cranial fossa (AFC) has always been a complex area of neurosurgery. The close relationship of the pathological processes of the PCN with large great vessels and cranial nerves required good visualization of this area through wide frontotemporal approaches [2,3]. More than 100 years have passed since the first description of frontal craniotomy for the removal of olfactory meningioma (Francesco Durante in 1885). Since then, surgical approaches have evolved from Dandy's extensive "macrosurgical" frontotemporal approaches to Yasargil's pterional approach to the micro-keyhole approaches developed by Pernetsky. The development of neuroimaging, neurosurgical instruments, the introduction of a microscope and endoscope, and improved illumination of the surgical field made these achievements possible [4,5,6].

In recent years, neurosurgery has been evolving in the direction of low-traumatic surgery, moving away from the central dogma of skull base surgery, which says that extensive craniotomy leads to less traction on the brain. However, it has been proven that extensive access leads to microtrauma of a large surface of the brain due to prolonged exposure to non-physiological conditions, exposure to ambient air, irrigation, various gauze materials and spatulas. As a result, this leads to the development of neurological deficit, epileptic seizures and infectious complications in the postoperative period. By reducing the size of the craniotomy, brain damage and the number of unwanted postoperative complications are significantly reduced. Therefore, the task of micro-approaches is not to minimize the size of the trepanation window, but to minimize brain injury. It is necessary to understand that the craniotomy should be as small as the brain injury will be minimal and as large as it can provide the most adequate and safe access.

Classic frontotemporal craniotomies provide good access to the base of the skull; however, craniotomies are often performed on areas of the skull that do not play a major role in access to a particular pathological formation. In addition, they have a number of complications such as atrophy of the temporal muscle, limited chewing function, and numbness of the skin of the forehead. Classical approaches take longer to perform, are associated with greater blood loss, cause significant swelling of the soft tissues of the face after surgery and in some patients an unsatisfactory cosmetic result, and also require a long stay for the patient in the hospital and high medication costs.

The term “keyhole” accurately reflects the essence of reducing the invasiveness of manipulations by significantly reducing the size of the craniotomy, when through a small burr hole the surgeon can visualize a sufficient area of the cranial cavity, which creates the surgical field necessary for manipulations on intracranial structures.

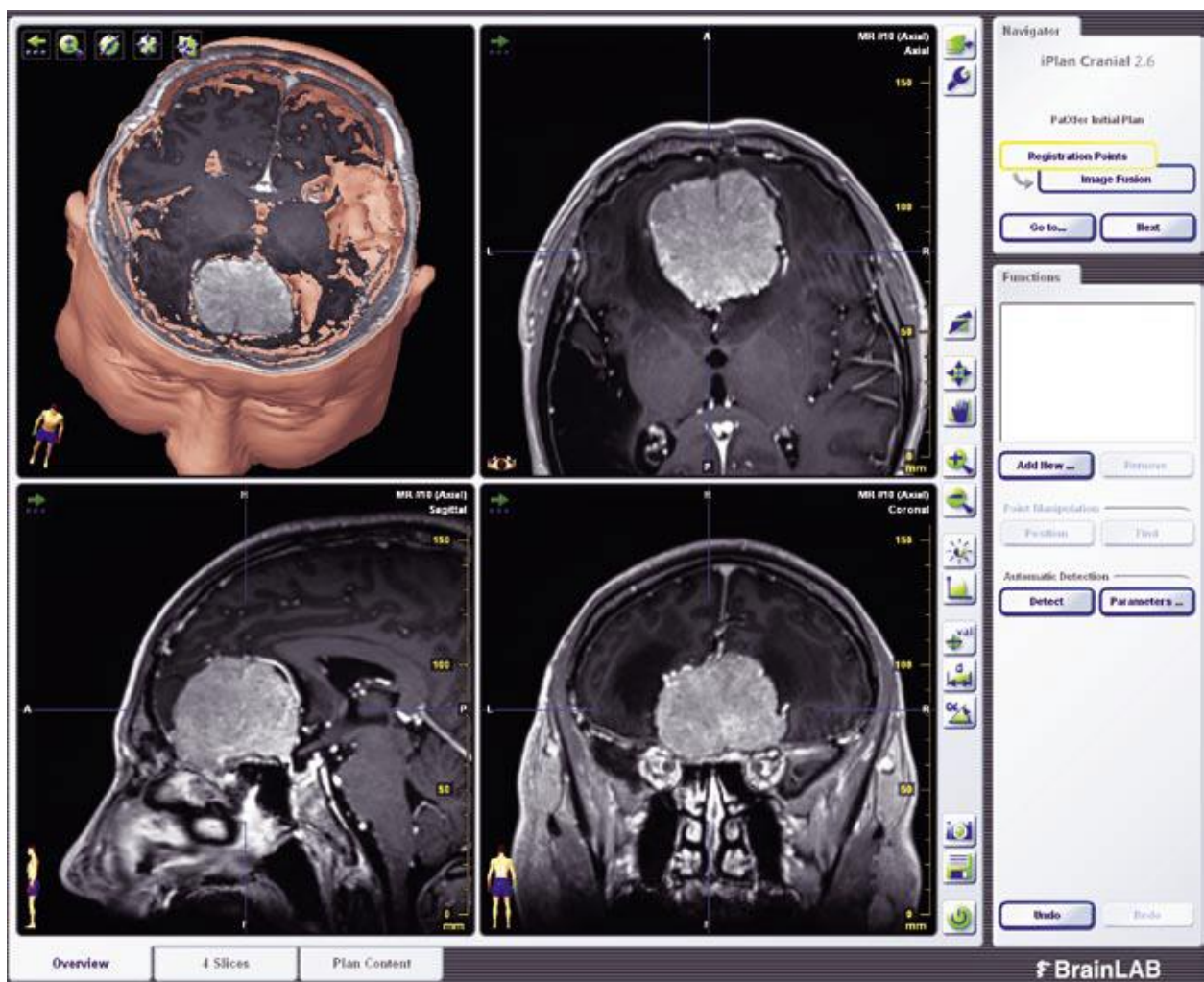
The patient underwent surgery: Pterional “keyhole” craniotomy on the right, total microsurgical removal of a neoplasm of the base of the anterior cranial fossa with growth into the 3rd ventricle using surgical techniques—microscope and intraoperative BrainLAB navigation system, neurophysiological monitoring.

Operation description. With the patient lying on his back, the head was rigidly fixed with the head turned 30 degrees to the left, the reference frame of the navigation system was installed, and the patient was registered. The tumor is isolated and removed from the basal parts of the right and left lobes of the brain. After performing a partial falxotomy, separation of the tumor capsule from the

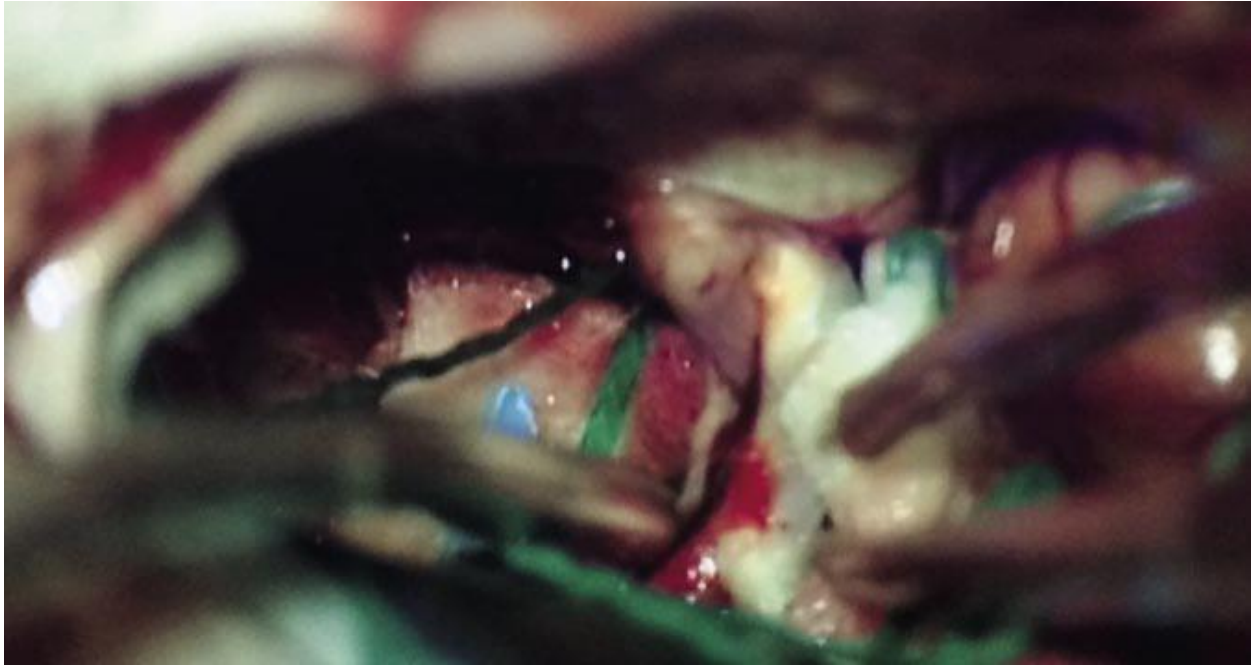
right and left anterior cerebral arteries, from the right and left optic nerves. The part of the tumor growing into the 3rd ventricle was reduced and removed. After total removal of a tumor measuring 5.0+6.0+4.0 cm, the right and left optic nerves straightened, and the supraclinoid part of the right internal carotid artery was visualized. Radicality of removal 2nd degree (according to D. Simpson, 1957). The bone flap is fixed with titanium craniofixes. Suturing the wound (Fig. 2).

Based on the results of control neuroimaging (multispiral computed tomography), ischemic and hemorrhagic changes in the brain in the postoperative period were excluded.

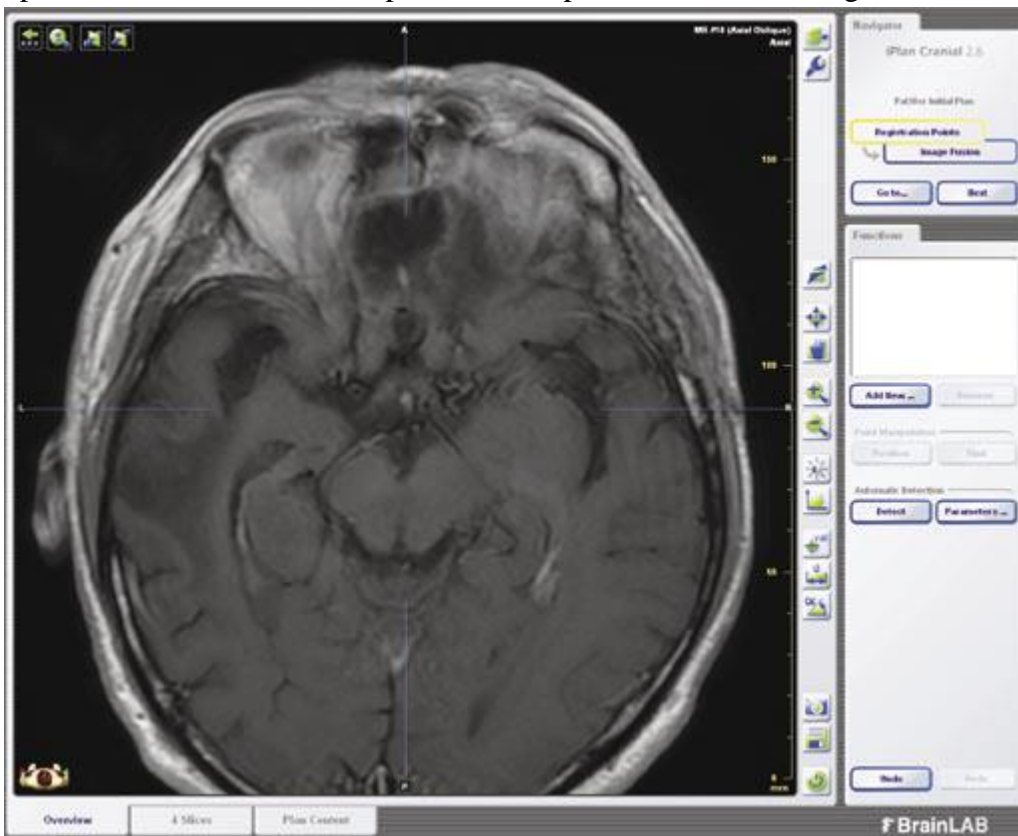
Using the “keyhole” approach, it was possible to perform total removal of the tumor at the base of the anterior cranial fossa without increasing neurological disorders.



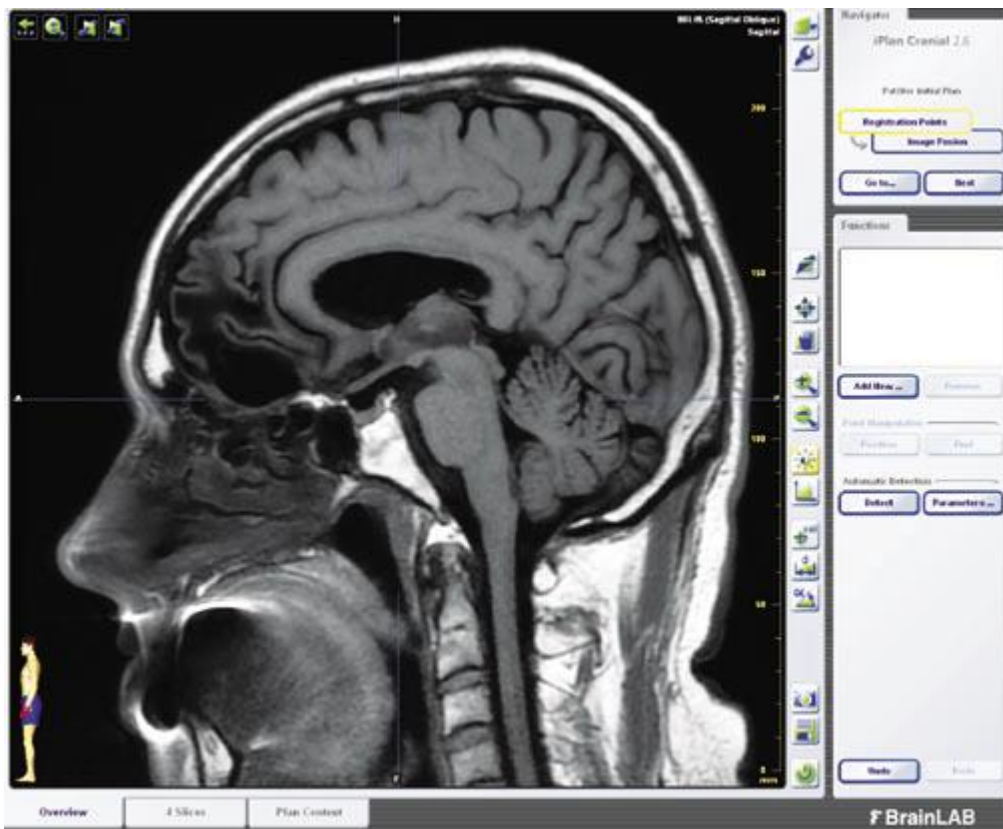
Rice. 1.MRI of the brain with contrast enhancement at the planning stage of neuronavigation



Rice.2. Intraoperative picture from a microscope. Green arrow: tumor tissue. Red arrow: right optic nerve. White arrow: supraclinoid part of the right internal carotid artery



Rice.3. Postoperative MRI of the brain - control (axial section)



Rice.4. Postoperative MRI of the brain - control (sagittal section) Histological conclusion: morphological picture of meningotheiomatous meningioma with foci of ossification, grade I. Research results. Activation of the patient to the following essence after the operation, healing of the postoperative wound by primary intention, a good cosmetic effect was noted. The duration of hospitalization was 7 days. After a control MRI of the brain with contrast enhancement 6 months later, no signs of tumor recurrence were noted (Fig. 3, 4). The patient fully recovered and returned to his normal lifestyle.

Conclusions

Early diagnosis and surgical treatment of brain meningiomas in most cases lead to complete cure of patients.

List of used literature

1. Alruwaili AA, De Jesus O. Meningioma. In: StatPearls [Internet]. Treasure Island (FL): StatPearls Publishing; 2022. PMID: 32809373.
2. Gatto L., Franceschi E., Di Nunno V., Tosoni A., Lodi R., Brandes AA Liquid Biopsy in Glioblastoma Management: From Current Research to Future Perspectives // *Oncologist*. 2021. - 26(10). - 865-878. doi: 10.1002/onco.13858. Epub 2021 Jun 23. PMID: 34105205; PMCID: PMC8488799.
3. Spallone A., Santoro A., Palatinsky E., Giunta F. Intracranial meningiomas associated with glial tumors: A review based on 54 selected literature cases from the literature and 3 additional personal cases // *Acta Neurochir (Wien)*. – 1991. – 110. - 133–9.
4. Goyal A., Singh AK, Sinha S., Tatke M., Singh D., Gupta V., et al. Simultaneous occurrence of meningioma and glioma in the brain: Report of two cases // *J Clin Neurosci*. – 2003. – 10. - 252–4.
5. Nestler U., Schmidinger A., Schulz C., Huegens-Penzel M., Gamerdinger U.A., Koehler A., et al. Glioblastoma simultaneously present with meningioma – report of three cases // *Zentralbl Neurochir*. – 2007. – 68. - 145–50.

6. Munjal S., Kumar J., Jain S., Mehta VS Glioma Simultaneously Present with Adjacent Meningioma: Case Report and Literature Review // *Asian J Neurosurg.* – 2019. - 14(1). - 272-274. doi: 10.4103/ajns.AJNS_308_17. PMID: 30937052; PMCID: PMC6417352.