

A Critical Assessment of Endoscopic Third Ventriculostomy Results an In-depth Analysis of Children

Dr. Mohammed Rashad Ismael Al-Jawaheri

M.B.Ch.B., F.I.B.M.S., M.D. \ (Specialists Neurosurgery)

Fellowship Hallym University, Seoul, South Korea.

Neurosurgeon at Neurosurgical Teaching Hospital, Al-Rusafa Health Directorate, Iraqi Ministry of
Health, Baghdad, Iraq.

Lecturer of Neurosurgery

Ministry of Higher Education and Scientific Research, Al-Iraqia University, Medical College, Baghdad,
Iraq.

mohammed.r.ismael@aliraqia.edu.iq

Dr. Ameer Majeed Kareem

M.B.Ch.B., F.I.C.M.S. \ (Neurosurgery)

Kurdistan Ministry of Health, Erbil Health Department, Erbil Teaching Hospital, Erbil, Iraq.

ameer_bakal@yahoo.com

Dr. Thaer Fawzi Jameel Aljassar

M.B.Ch.B., F.I.C.M.S. \ (Neurosurgery)

Specialist Neurosurgeon

Iraqi Ministry of Health and Environment, Baghdad Al-Rusafa Health Directorate, Dr. Saad Al-Witry
Hospital for Neurosciences, Baghdad, Iraq.

aljassar_2006@yahoo.com

Abbas AbdulWahhab Jumaah Al-Salihi

Department of Applied Embryology, High Institute for Infertility Diagnosis and Assisted Reproductive
Technologies, Nahrain University, Kadhimiya, Baghdad, Iraq.

Abbasabdulwahhab@ierit.nahrainuniv.edu.iq

Dr. Salim Mardan Omer

M.B.Ch.B., F.I.C.M.S. (Neurosurgery)

Ministry of Higher Education and Scientific Research, Kirkuk University \ College of Medicine, Kirkuk,
Iraq.

salimaljabbary@yahoo.com

Dr. Tareq Jawad kadem Al-Rubayee

M.B.Ch.B., M.R.C.S., Ireland

Diploma General Surgery

Ministry of Higher Education and Scientific Research, AL-Rasheed University College, Department of
Pharmacy, Baghdad, Iraq.

dr.tariq.jawad@alrasheedcol.edu.iq

Abstract

Background: The endoscopic third ventriculostomy of the third ventriculostomy is a surgical procedure offered to children and adults diagnosed with obstructive or non-communicating hydrocephalus. **Objective:** This study assessed and analyzed the surgical outcomes of children who underwent endoscopic third ventriculostomy (ETV). **Patients and methods:** 115 pediatric patients with hydrocephalus, whose ages ranged from less than three months to 13 years, were recruited. Clinical data for the third ventriculostomy procedure were collected from different hospitals in Iraq in the period from January 14, 2022, to September 28, 2023, where patients' clinical data included all of the causes resulting from hydrocephalus, the duration of the operation, the duration of follow-up and recovery, the success and failure rate of the operation, the length of stay in the hospital, the complication rate, and the patient's quality of life. **Results:** Our results show that demographic data of children patients shows that children aged 7–13 years had the highest rate, which included 50 cases, while males had the highest rate, which included 74 cases compared with 41 cases for females, as well as causes of hydrocephalus, whose most common prevalence was stenosis of the cerebral aqueduct, which included 40 cases, and brain tumors, which included 49 cases. We enrolled clinical findings of children who underwent an ETV procedure surgically, where the time of endoscopic third ventriculostomy was 1.46 ± 0.21 , the length of stay in hospital was 2.80 ± 1.02 days, successful access to surgery included 104 patients, failed access to surgery included 11 cases, and the rate of complications was 25.22% of total patients, which included CSF leaks in 9 cases, hyponatremia in 6 cases, and pseudo meningocele in 5 cases. **Conclusion:** This study indicated that endoscopic third ventriculostomy (ETV) is the safest and most effective surgical procedure in the treatment of pediatric patients with hydrocephalus, which results in a high success rate for the operation and results in the recovery of pediatric patients.

Key words: *Endoscopic Third Ventriculostomy (ETV); Children; Quality of life; and Hydrocephalus*

Introduction

Endoscopic third ventriculostomy (ETV) is a minimally invasive surgical procedure that is performed through a single hole in the skull (monoportal) with the use of a neuroendoscope that allows the fenestration of the floor of the third ventricle to be performed, thus communicating the ventricular system with the subarachnoid space. [1,2]

Hydrocephalus is a condition in which a buildup of cerebrospinal fluid (CSF) occurs inside the brain [3]. This usually causes an increase in pressure inside the skull. Excess fluid puts pressure on the brain and can cause brain damage [4]. It is more common in infants and older adults [5]. This surgery is performed to drain excess cerebrospinal fluid (CSF) from the brain. The extra cerebrospinal fluid accumulates and enlarges the ventricles of the brain. The third ventriculostomy refers to the area of the brain where the bypass is performed [4,6,7]. Because the most common site of obstruction is the narrow pathway between the third and fourth ventricles of the brain, the shunt is made through the thin membrane in the third ventricle. The most common symptoms of hydrocephalus include headache, nausea, problems with thinking and memory, and irritability. [6,8,3,4]

In neurosurgery, hydrocephalus is still a common problem that requires numerous short-term fixes, particularly in cases of obstructive hydrocephalus, where intracranial hypertension syndrome frequently coexists and poses a risk to the patients' lives. [9 – 12]

Even though there have been improvements in valved shunt technology, there are still a lot of revisions that need to be done because of problems or infections in the ventriculoperitoneal or ventriculo-atrial shunt valves. [13]

Many people have heard of the idea of an internal bypass that doesn't require a valve to be put in place [14]. Several techniques have been described, including the lamina terminalis microsurgical opening of the floor of the third ventricle, the stereotactic perforation of the floor of the third ventricle, aqueductoplasty [15], and the Torkildsen ventriculocisternostomy. The endoscopic third ventriculostomy (EVT), which results in a straightforward and efficient technique in the treatment of hydrocephalus and permits adequate management of endocranial hypertension, has largely replaced these methods. [16,17]

If the cerebrospinal fluid (CSF) is blocked in a way that causes hydrocephalus, the EVT makes a way for the CSF to get back into the body at the level of the arachnoid granulations of the convexity. This is done by creating an internal bypass between the cerebral ventricles and the subarachnoid space of the cisterns at the base of the skull. [18,19]

EVT has been the springboard of pediatric neurosurgeons since its inception, with conclusions on exclusively pediatric populations or on mixed groups of pediatric populations being found in most reports, with studies conducted solely on children. [20]

Patients and methods

We conducted a cross-sectional study of pediatric patients suffering from hydrocephalus, in which all patients underwent the surgical procedure of laparoscopic third ventriculostomy. The study included 115 children who were diagnosed and had the surgical procedure performed, and their ages ranged from less than three months to 13 years where all databases were collected from different hospitals in Iraq with the period between 14 January 2022 to 28 September 2023.

During the first follow-up period, basic diagnostic information about pediatric patients was gathered. This information included the patients' ages, genders, the causes and effects of hydrocephalus in children, the types of hydrocephalus found during diagnosis, and signs that were found in pediatric patients during the infection period. Furthermore, we distributed the probability of propensity scores by treatment for endoscopic third ventriculostomy patients, with a range between 0 and 1.

Regarding surgical outcomes, this study identified clinical data for pediatric patients who underwent a third ventriculostomy, which included the duration of surgery, the duration of follow-up and recovery, the type of endoscope used (flexible and rigid), the degree of internal bleeding (none, mild, moderate, and severe), the duration of hospital stay, and the rate of success and failure of the procedure. We also distributed the definition of successful outcomes for pediatric patients who underwent endoscopic third ventriculostomy (ETV).

Regarding postoperative outcomes, this study was conducted by recording recovery rates, length of hospital stays, rate of complications, and quality of life that were associated with pediatric patients with hydrocephalus, which were determined by criteria that included the physical health score, the cognitive health score, the social and emotional health score, and the final score. Furthermore, this study reported outcomes associated with determining the postoperative survival rate of pediatric patients who underwent ETV during a 30-month follow-up. The clinical results were designed, recorded, analyzed, and distributed to all pediatric patients using SBS version 22.0.

Results

Table 1: Clinical and demographic characteristics of children's patients who underwent to endoscopic third ventriculostomy [ETV].

Characteristics	Children patients [115]	Percentage [%]
Age		
< 3 months	6	5.22%
3 – 8 months	9	7.83%
9 – 12 months	18	15.65%
1 – 6 years	32	27.83%
7 – 13 years	50	43.48%
Sex		
Males	74	64.35%
Females	41	35.65%
Causes of hydrocephalus		
Stenosis of cerebral aqueduct	40	34.78%
Brain tumor	49	42.61%
Post intraventricular hemorrhage	10	8.70%
Myelomeningocele	4	3.48%
Craniosynostosis	7	6.09%
Posterior fossa cyst	3	2.61%
Others	2	1.74%
Type of hydrocephalus		
Non communicating	93	80.87%
Communicating	22	19.13%

Our results shown demographic data of children patients where children with 7 – 13 years were highest which, include 50 cases, followed by children with (1 – 6) years were 32 cases, where males had the most rates which, include 74 to compare with females included 41 cases. Our findings found patients which have hydrocephalus with communicating were 22, and non – communicating were 93 cases. Our outcomes were defined causes of hydrocephalus, which is the most common prevalence, which are stenosis of the cerebral aqueduct, which included 40 cases, and brain tumor, which included 49 cases.

Table 2: Distribution of probability of propensity scores by treatment for endoscopic third ventriculostomy patients.

Propensity scores of treatments	Number of cases	Percentage [%]
0.06	2	1.74%
0.10	4	3.48%
0.20	2	1.74%
0.40	3	2.61%
0.60	13	11.30%
0.80	56	48.70%
1.0	35	30.43%

In Figure 1, we determined indications of children patients with hydrocephalus, which have rapidly increasing head size, had 28 cases, bulging fontanelle had 36 cases, and downward deviation of the eyes had 21 cases.

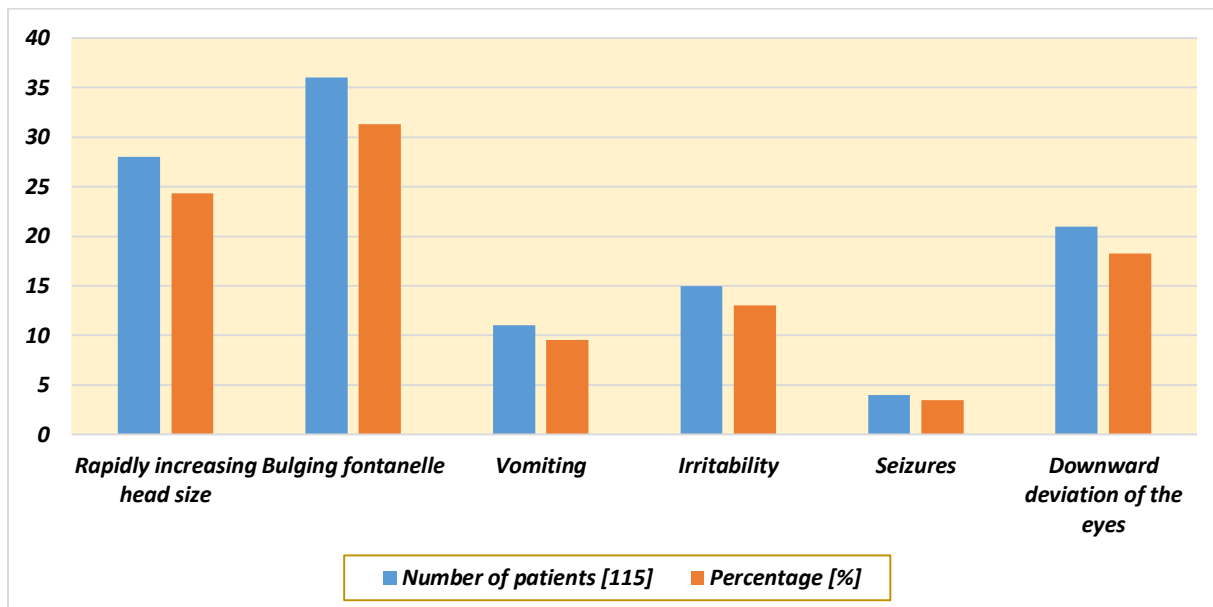


Figure 1: Distribution of common indications of children patients with hydrocephalus.

Table 3: Surgical outcomes associated with children's patients with hydrocephalus who underwent to endoscopic third ventriculostomy.

Variables	Number of patients [115]	Percentage [%]
<i>Time of endoscopic third ventriculostomy (mean ± SD)</i>	1.46 ± 0.21	
<i>Type of endoscope used</i>		
Flexible	14	12.17%
Rigid	101	87.83%
<i>Degree of intraop bleeding</i>		
None	77	66.96%
Mild	30	26.09%
Moderate	6	5.22%
Severe	2	1.74%
<i>Recovery time, weeks</i>	1.73 ± 0.26	
<i>Length of stay in hospital, days</i>	2.80 ± 1.02	
<i>Surgical access</i>		
Successful	104	90.43%

Our findings were enrolled surgical data of children who underwent to ETV surgery where the time of endoscopic third ventriculostomy (mean \pm SD) was 1.46 ± 0.21 , the degree of intraop bleeding was including none with 77 cases while severe had only 2 cases, length of stay in hospital was 2.80 ± 1.02 days, recovery time was 1.73 ± 0.26 weeks, successful access of surgery included 104 patients while failed access of surgery included 11 cases.

Table 4: Identify successful scores of children patients who underwent by endoscopic third ventriculostomy (ETV).

<i>ETVSS</i>	<i>Number of patients [115]</i>	<i>Percentage [%]</i>
10	1	0.87%
20	1	0.87%
30	2	1.74%
40	4	3.48%
50	6	5.22%
60	8	6.96%
70	28	24.35%
80	46	40.0%
90	19	16.52%

According to Figure 2, our results were enrolled postoperative complication associated with endoscopic third ventriculostomy (ETV) where the rate of complications were 25.22% of total patients, which include CSF leak had 9 cases, hyponatremia had 6 cases, and pseudo meningocele had 5 cases.

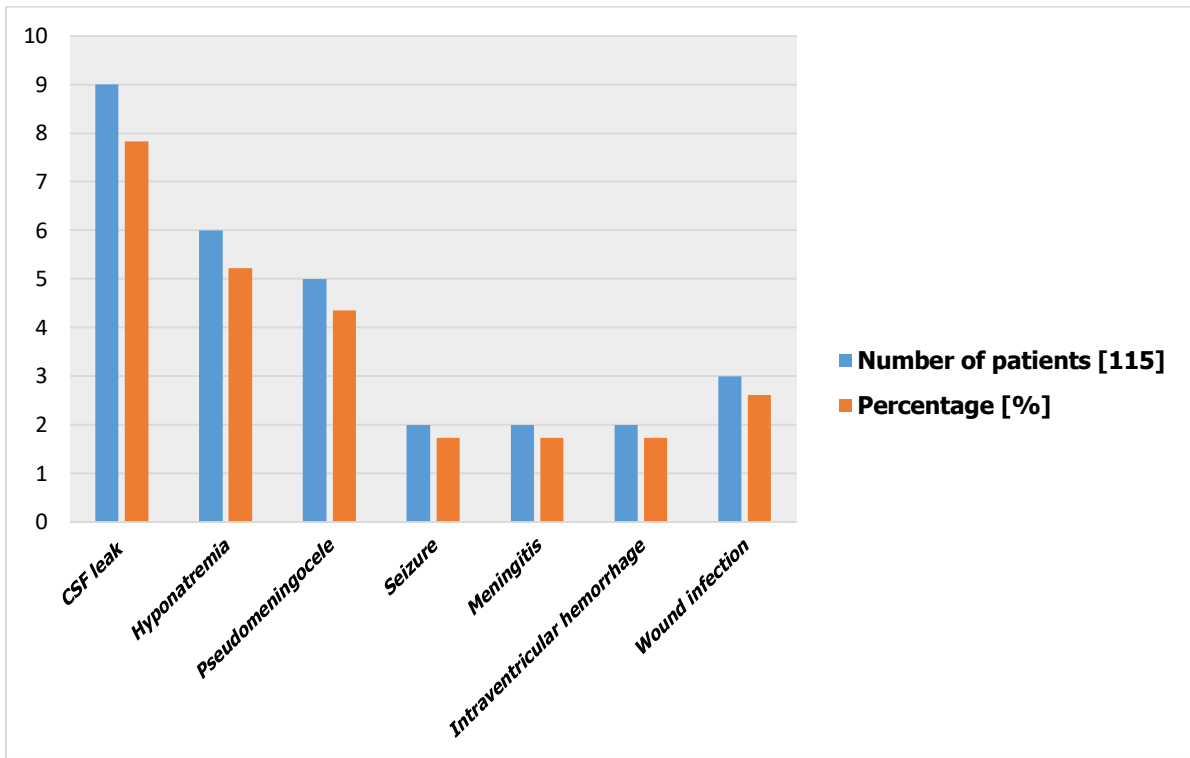


Figure 2: Postoperative of ETV complications.

Table 5: Assessment of quality-of-life patients with hydrocephalus who underwent to endoscopic third ventriculostomy.

Outcome's measure	ETV surgical treatment
<i>Physical health score</i>	0.78 ± 0.21
<i>Cognitive health score</i>	0.62 ± 0.28
<i>Social-emotional health score</i>	0.71 ± 0.18
<i>Overall score</i>	0.76 ± 0.20

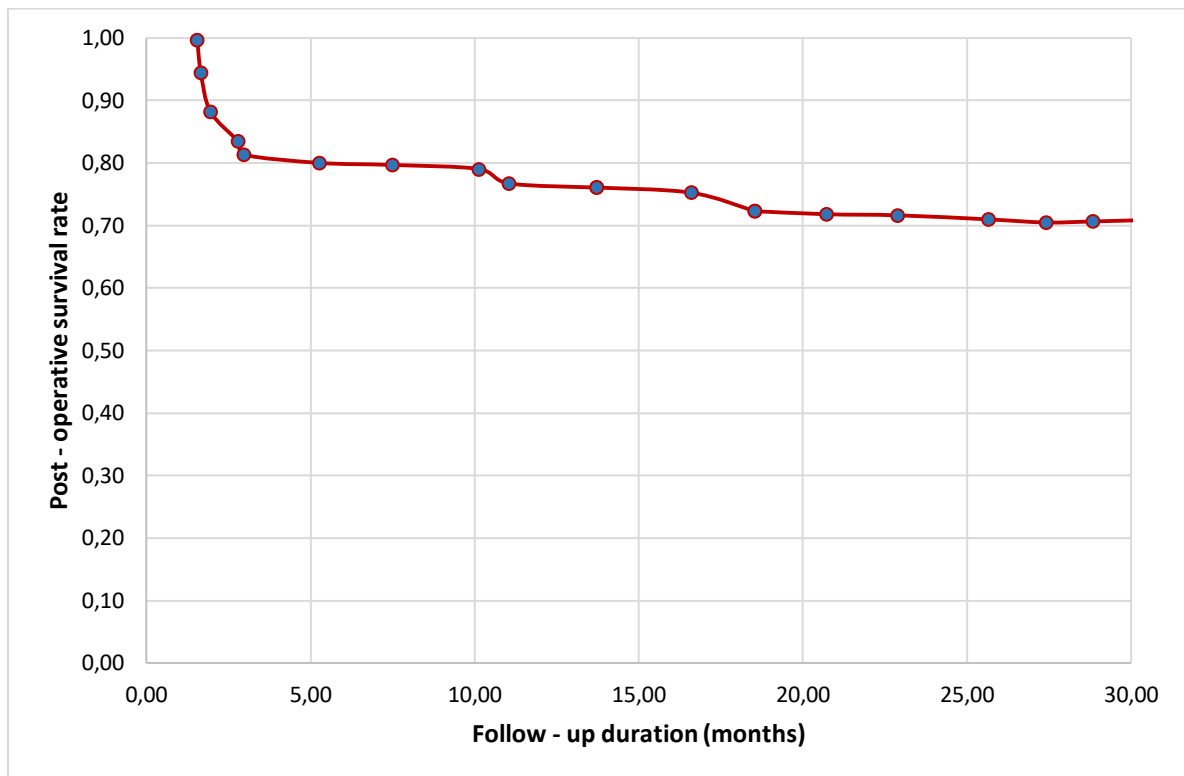


Figure 3: Determine the post-operative survival rate of children patients who underwent to ETV during follow-up.

Discussion

The surgical intervention known as Endoscopic Third Ventriculostomy (ETV) had performed on juvenile individuals diagnosed with hydrocephalus, which is a medical disorder that can define throughout the atypical buildup of cerebrospinal fluid inside the brain [21]. An American study has found that ETV can serve as a viable therapeutic option in juvenile patients suffering into hydrocephalus, where the underlying cause of the problem was a blockage of the ventricular system where ETV had shown a decreased in terms of infection in comparison to conventional shunt insertion operations, and it may also diminish the need for further surgeries. [22]

Nevertheless, it was crucial of acknowledge that the efficacy in ETV of pediatric patients can differ based on many circumstances, which include the primary cause of hydrocephalus, the patient's age, and the proficiency of the surgical team doing the treatment, where ETV has inherent hazards that contain infection, hemorrhage, and the possibility of insufficient treatment of the hydrocephalus. [23]

Pediatric patients had encountered pain and discomfort after undergoing ETV, that alleviates of the administration of medicine given by their healthcare professional where the degree of discomfort encountered was exhibits variability across individuals, and electrothermal therapy (ETV) has the potential which improve the quality of life in young patients afflicted with illnesses in terms of hydrocephalus, which it can be achieved by the efficient reduction of cerebrospinal fluid accumulation inside the brain [24]. In addition, factors were resulted to enhance cognitive abilities, increased physical mobility, and general state of health, which the expense of ETV might fluctuate determined throughout several elements that include the medical

establishment, healthcare practitioner, geographical area, and insurance coverage, where ETV was regarded as a cost-effective therapy choice. [25]

Furthermore, the pace of recovery after ETV was differ across juvenile patients. Which certain people can have a comparatively expeditious recuperation with minor difficulties, whilst others may need a longer duration to achieve complete recovery where adherence to post-operative instructions had been provided throughout healthcare providers, which is defined as important for patients in order to promote a seamless recovery process [26]? Although ETV was shown as generally regarded within a secure and efficient technique, it was important to determine the possible hazards and consequences which may arise from the surgery, including infection, hemorrhage, or leaking of cerebrospinal fluid, where the probability of encountering problems can differ across patients, contingent upon variables in terms of age, general well-being, and the underlying medical condition under consideration. [27]

Conclusion

Our current study shows endoscopic third ventriculostomy (ETV) as the best surgical procedure, and the most effective treatment option to treat all pediatric patients with hydrocephalus due to its advantages of a faster recovery rate, a lower pain rate, and a lower cost rate compared with other surgeries, and rate of complications is reduced, where it is attributed to an improvement in general health and cognitive function in pediatric patients in an optimal and safe way compared to other surgical procedures.

LITERATURE

1. Azimi P, Mohammadi HR: Predicting endoscopic third ventriculostomy success in childhood hydrocephalus: an artificial neural network analysis. *J Neurosurg Pediatr* 13:426–432, 2014
2. Bouras T, Sgouros S: Complications of endoscopic third ventriculostomy. *J Neurosurg Pediatr* 7:643–649, 2011
3. Breimer GE, Sival DA, Brusse-Keizer MGJ, Hoving EW: An external validation of the ETVSS for both short-term and long-term predictive adequacy in 104 pediatric patients. *Childs Nerv Syst* 29:1305–1311, 2013
4. Chamiraju P, Bhatia S, Sandberg DI, Ragheb J: Endoscopic third ventriculostomy and choroid plexus cauterization in posthemorrhagic hydrocephalus of prematurity. *J Neurosurg Pediatr* 13:433–439, 2014
5. Durnford AJ, Kirkham FJ, Mathad N, Sparrow OC: Endoscopic third ventriculostomy in the treatment of childhood hydrocephalus: validation of a success score that predicts long-term outcome. *J Neurosurg Pediatr* 8:489–493, 2011
6. Foroughi M, Wong A, Steinbok P, Singhal A, Sargent MA, Cochrane DD: Third ventricular shape: a predictor of endoscopic third ventriculostomy success in pediatric patients. *J Neurosurg Pediatr* 7:389–396, 2011
7. Furlanetti LL, Santos MV, de Oliveira RS: The success of endoscopic third ventriculostomy in children: analysis of prognostic factors. *Pediatr Neurosurg* 48:352–359, 2012
8. García LG, López BR, Botella GI, Páez MD, da Rosa SP, Rius F, et al.: Endoscopic Third Ventriculostomy Success Score (ETVSS) predicting success in a series of 50

- pediatric patients. Are the outcomes of our patients predictable? *Childs Nerv Syst* 28:1157–1162, 2012
9. Greenfield JP, Hoffman C, Kuo E, Christos PJ, Souweidane MM: Intraoperative assessment of endoscopic third ventriculostomy success. *J Neurosurg Pediatr* 2:298–303, 2008
 10. Kombogiorgas D, Sgouros S: Assessment of the influence of operative factors in the success of endoscopic third ventriculostomy in children. *Childs Nerv Syst* 22:1256–1262, 2006
 11. Kulkarni AV, Donnelly R, Mabbott DJ, Widjaja E: Relationship between ventricular size, white matter injury, and neurocognition in children with stable, treated hydrocephalus. *J Neurosurg Pediatr* 16:267–274, 2015
 12. Kulkarni AV, Drake JM, Armstrong DC, Dirks PB: Imaging correlates of successful endoscopic third ventriculostomy. *J Neurosurg* 92:915–919, 2000
 13. Kulkarni AV, Drake JM, Kestle JR, Mallucci CL, Sgouros S, Constantini S: Endoscopic third ventriculostomy vs cerebrospinal fluid shunt in the treatment of hydrocephalus in children: a propensity score-adjusted analysis. *Neurosurgery* 67:588–593, 2010
 14. Kulkarni AV, Drake JM, Kestle JRW, Mallucci CL, Sgouros S, Constantini S: Predicting who will benefit from endoscopic third ventriculostomy compared with shunt insertion in childhood hydrocephalus using the ETV Success Score. *J Neurosurg Pediatr* 6:310–315, 2010
 15. Kulkarni AV, Drake JM, Mallucci CL, Sgouros S, Roth J, Constantini S: Endoscopic third ventriculostomy in the treatment of childhood hydrocephalus. *J Pediatr* 155:254–259.e1, 2009
 16. Kulkarni AV, Riva-Cambrin J, Browd SR: Use of the ETV Success Score to explain the variation in reported endoscopic third ventriculostomy success rates among published case series of childhood hydrocephalus. *J Neurosurg Pediatr* 7:143–146, 2011
 17. Kulkarni AV, Riva-Cambrin J, Browd SR, Drake JM, Holubkov R, Kestle JRW, et al. Endoscopic third ventriculostomy and choroid plexus cauterization in infants with hydrocephalus: a retrospective Hydrocephalus Clinical Research Network study. *J Neurosurg Pediatr* 14:224–229, 2014
 18. Naftel RP, Reed GT, Kulkarni AV, Wellons JC: Evaluating the Children’s Hospital of Alabama endoscopic third ventriculostomy experience using the Endoscopic Third Ventriculostomy Success Score: an external validation study. *J Neurosurg Pediatr* 8:494–501, 2011
 19. Nikas DC, Post AF, Choudhri AF, Mazzola CA, Mitchell L, Flannery AM: Pediatric hydrocephalus: systematic literature review and evidence-based guidelines. Part 10: Change in ventricle size as a measurement of effective treatment of hydrocephalus. *J Neurosurg Pediatr* 14 (Suppl 1):77–81, 2014
 20. Rasul FT, Marcus HJ, Toma AK, Thorne L, Watkins LD: Is endoscopic third ventriculostomy superior to shunts in patients with non-communicating hydrocephalus? A systematic review and meta-analysis of the evidence. *Acta Neurochir (Wien)* 155:883–889, 2013.
 21. Kulkarni AV, Sgouros S, Constantini S, Investigators IIHS (2016) International infant hydrocephalus study: initial results of a prospective, multicenter comparison of endoscopic third ventriculostomy (ETV) and shunt for infant hydrocephalus. *Childs Nerv Syst* 32 (6):1039–1048.
 22. Tewuerbati S, Maimaitili M, Zhu G, Du G, Liu B, Sailike D, Fan Y, Dangmurenjiafu G (2015) Timing of endoscopic third ventriculostomy in pediatric patients with congenital obstructive hydrocephalus: assessment of neurodevelopmental outcome and short-term operative success rate. *J Clin Neurosci* 22 (8):1292–1297.
 23. Weil AG, Westwick H, Wang S, Alotaibi NM, Elkaim L, Ibrahim GM, Wang AC, Ariani RT, Crevier L, Myers B, Fallah A (2016) Efficacy and safety of endoscopic third

- ventriculostomy and choroid plexus cauterization for infantile hydrocephalus: a systematic review and meta-analysis. *Childs Nerv Syst* 32 (11):2119–2131.
24. Baird LC (2016) First treatment in infants with hydrocephalus: the case for endoscopic third Ventriculostomy/choroid plexus cauterization.
 25. Wagner W, et al. Mechanisms of failure after endoscopic third ventriculostomy in young infants. *J Neurosurg (Pediatrics 1)*. 2005; 103:43–9.
 26. Abdel-Aziz KI, Nouby R, Thabet MA, Elshirbiny MF. Endoscopic Third Ventriculostomy versus Ventriculoperitoneal Shunt for Infant Hydrocephalus. *Open J Modern Neurosurg*. 2020; 10:193–202.
 27. Mohammadi H, Sadat M, Khayat KH. Evaluation of long-term outcomes and prediction of the failure rate of endoscopic third ventriculostomy in less than two years children. *Int Clin Neurosci J*. 2020;7 (2):66–70.