

The Unique Morphological Structure of the White Outbred Rat Prostate Gland

Karimov Hakimjon Rayimberdievich

Assistant of the Department of Pathological Anatomy, Bukhara State Medical
Institute

Abstract: This article presents information from local and foreign sources about the anatomical structure, histology, morphogenesis, and characteristic features of the prostate gland of the white outbred rat.

Key word: Rat prostate anatomy, histology, embryogenesis, specific morphological structure.

Introduction is the main part

Reproductive organs: In young rats (130-150 g), the weight of both testicles is 0.7 g, in adults (200-250 g) 2.5 g. There are few interstitial cells in the testicles. The testicles are elliptical in shape, often located in the scrotum and can be pulled into the inguinal tract.

There is a bone in the body of the penis. Like rabbits, rats have a well-defined male uterus that opens into the urogenital tract. The prostate gland is well developed

Macroscopic anatomy

The anatomy of the prostate varies greatly between species, but it is usually located below the bladder and in front of the rectum. The prostate is a compact structure in men and dogs, but consists of several lobes in rats and mice. The mouse prostate consists of four lobes with different morphological characteristics, commonly referred to as the ventral, lateral, dorsal, and anterior lobes, and classified according to their location relative to the urinary bladder (Figure 1).

Microscopic anatomy

The rat prostate gland is a highly specialized tubulo-alveolar exocrine gland. It consists of four distinct paired (right and left) lobes, posterior prostate gland, lateral prostate gland, ventral prostate gland, and anterior prostate gland or prostate gland. urethra, into which the ducts of the glands flow. Each part of the prostate has its own histology. It is important that each gland is fully represented and correctly defined for the assessment of histopathological criteria. Reliable identification of segments depends on obtaining a cut section that preserves each segment's anatomical relationship to the others and to the urinary tract.[3]

The ampullary gland in rats is structurally the smallest of the accessory gonads of male rodents, and differs from other glands in that it opens directly into the ampullary part of the deferent duct rather than into other glands. [10] In rats, spermatozoa are ampullary. because of secretions from the vas deferens in addition to secretions from the gland, the ampullary gland has been thought to influence sperm maturation and be important in assessing male reproductive toxicity.[13]

Normal ampullary glands in the rat surround the vas deferens. The alveoli are large, uniform in size, and surrounded by a few smooth muscle cells and connective tissue stroma. Strong eosinophilic secretions are often observed in the alveoli. The epithelium is flattened into cuboidal secretory cells with centrally located nuclei and some basal cells (Cleary, Choi, and Ayala 1983; Brawick and Mardi 1983; Hayward et al. 1996).

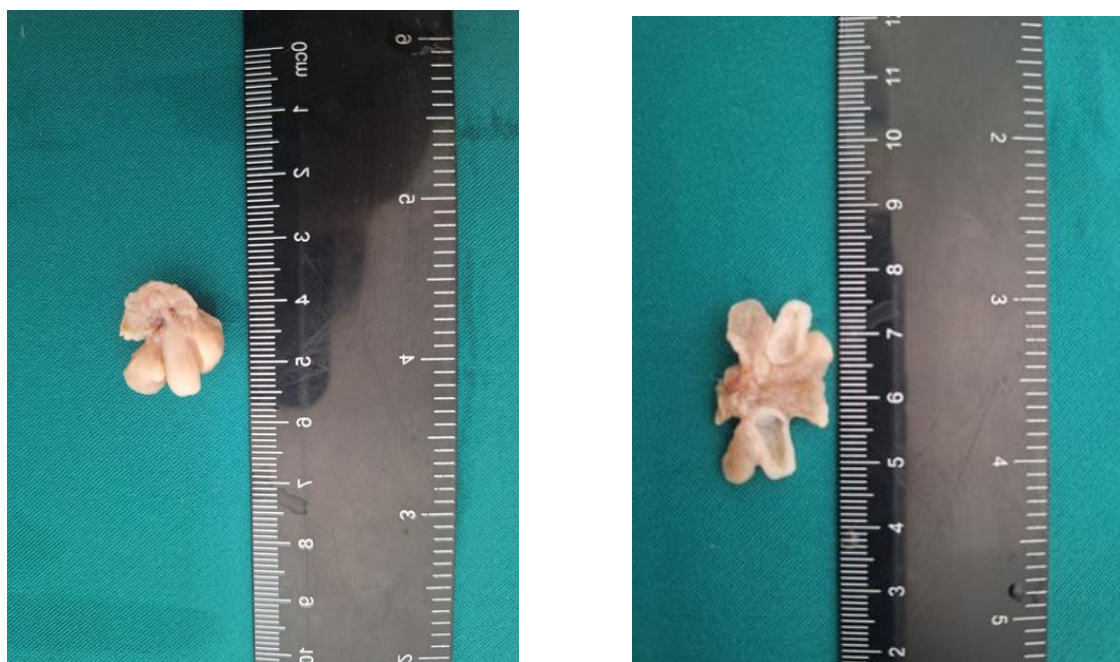

Figure 1 Gross view of rat male urogenital organs. Anterior and posterior views of the prostate gland of a 6-month-old white outbred male rat.

Histologically, prostate pieces are surrounded by a thin mesothelial connective capsule. Each lobe consists of individual glands (alveoli or acinus) and a series of branching ducts that flow independently into the urethra. Acinus are distinguished by a thin loose connective tissue containing stromal cells, cross-sectional smooth muscle cells, vessels, nerves, ganglia, macrophages, and mast cells. The cells lining the acini and ducts include luminal secretory cells, non-secretory basal cells (less common, accounting for 2% of acinar cells) and a small number of neuroendocrine cells. The luminal cells vary from cuboidal to tall columnar, and the height of the cells depends on the degree of secretory activity and enlargement of the gland. Acinus are surrounded by smooth muscle, which contract and secrete prostatic secretions; depending on the secretory activity, the fragments are filled with a proteinaceous secretion that is slightly eosinophilic.

The dorsal prostate lies below and behind the junction of the seminal vesicle and prostate gland and surrounds the urethra posteriorly. Microscopically, it resembles the prostate gland. The acinus is small with reduced epithelial shrinkage and is loosely distributed within the stroma.

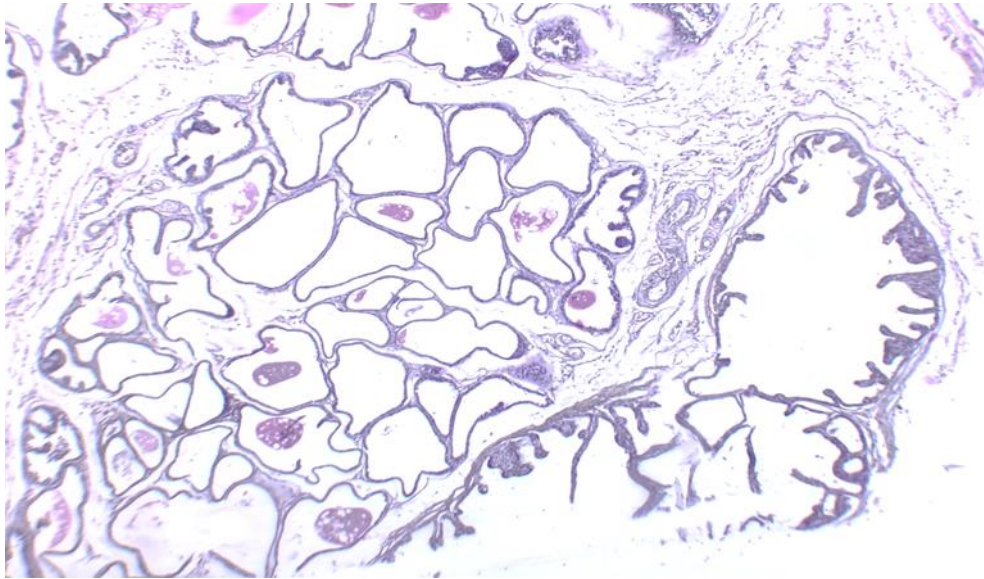


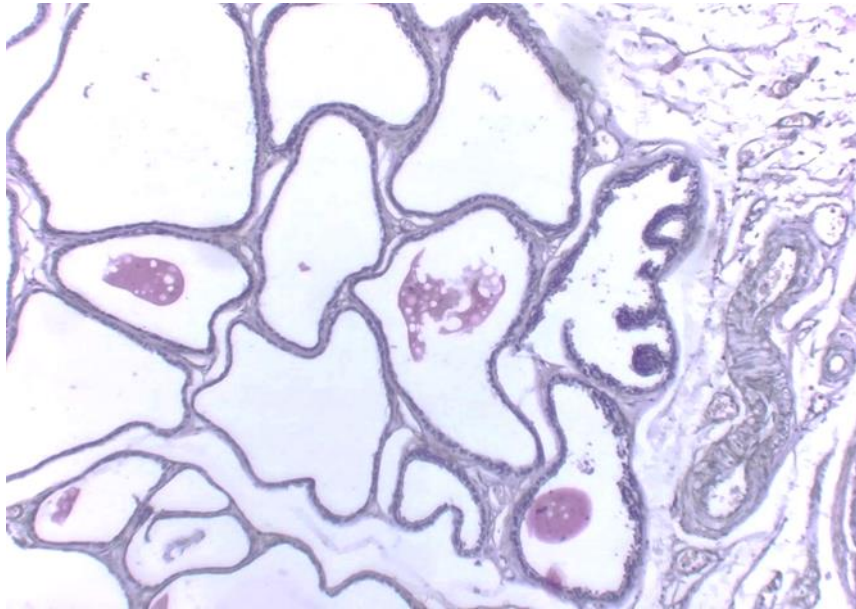
Figure 2.
Microscopic
view of the
prostate
gland of a

white outbred rat. Hemocillin is stained with eosin dye. Magnified 200 times. The ventral prostate is lined by columnar cells with basal nuclei and supranuclear cytoplasmic clear areas. Prostate gland is densely packed, alveolar-tubular gland. Surrounded by a prominent fibromuscular capsule.

Acinar cells are usually cuboidal, but can vary from cuboidal to columnar with cytoplasmic vesicles and centrally located nuclei. The acini are surrounded by a thin fibrous muscle layer and contain some eosinophilic secretion that stains an intermediate color between the secretions of the lateral and ventral lobes.[1]

The lateral prostate is located beneath the seminal vesicle and prostate gland and is lined with simple cuboidal to tall columnar epithelium, with basal nuclei and several intermediate layers of epithelium. These cells contain eosinophilic cytoplasm, which is less granular than that of the dorsal prostate, and conspicuous pale supranuclear areas with a characteristic brush border. Due to the relative difficulty of anatomical individualization of the dorsal and lateral lobes and similar histological features, these lobes are usually classified as a single element called the dorsolateral prostate.

The ventral prostate occurs on the ventral side of the bladder, immediately below the bladder. It is the largest piece, making up about half of all prostate tissue, and is the easiest to separate from the rest of the prostate gland. It consists of acinus of various sizes located close to each other, covered by a low to high columnar epithelium, basophilic cytoplasm basally located nucleus and supranuclear clear area. The glands are poorly infiltrated, surrounded by very little smooth muscle, and have pale eosinophilic serous or flocculent secretions.



3.
view of the
of a white
Hemocilline

eosin dye. Magnified 200 times Dorsal prostate: composed of cuboidal, columnar cells with cytoplasmic vesicles.

Figure
Microscopic
prostate gland
outbred rat.
is stained with

The prostate gland is sometimes called the dorsocranial, cranial, or anterior prostate and lies adjacent and parallel to the anterior surface of the seminal vesicle. Acinus are tightly coiled and surrounded by a prominent layer of fibrous muscle. The glands are lined by simple cuboidal to columnar epithelium, with eosinophilic granular cytoplasm, a centrally located nucleus, and inconspicuous nucleoli.

The prostate gland of both species embryologically originates from the urogenital sinus (UGS), an endoderm structure present in embryos at the ambisexual stage. Epithelial cells of the UGS form solid buds that invade the surrounding UGS mesenchyme in different directions at 10 weeks of gestation in humans and 17 days of gestation in rats. These precise locations define the bases of the different sections of the mouse prostate gland and the different zones of the human prostate described above. In humans, the prostatic bud elongates, undergoes branched morphogenesis, and shows signs of secretory differentiation by 14 weeks of gestation, with the prostate nearly fully developed at birth. In contrast, branching morphogenesis occurs postnatally in rats, and lobe-specific branching patterns are completed by 15 to 20 days. In both species, the prostate grows and matures rapidly, with blood androgen levels peaking at puberty (25–40 days of age in white outbred rats).

All parts of the rat prostate are surrounded by a thin capsule covered with mesothelium and separated from each other by fibrous connective tissue. Acinus forming parts of the prostate are surrounded by a fibromuscular capsule and placed in a sparse connective tissue with several stromal cells and collagen fibers. Nerve bundles and associated ganglia are often located in the connective tissue of the DLP. each of the white sterile rat prostate sections has a unique histology and can be seen under the microscope based on their location in relation to the ureters and seminal vesicles. VP has medium to large acinus, which are mainly composed of cuboidal or simple columnar epithelial cells with nuclei containing small nuclei. The luminal spaces of the VP glands are lined by a smooth mucosa, which shows minimal infolding or some focal epithelial tufting compared to other lobes. Each gland of the VP is surrounded by a thin fibromuscular layer. There are homogeneous pale serous secretions in the cavity of the glands.

Conclusions. The rat prostate has a distinct anatomy and histology, despite its embryological development, cellular composition, and molecular characteristics similar to the human prostate. A comprehensive understanding of the normal anatomy and histology of the white outbred rat prostate gland is therefore essential to draw definitive conclusions from studies conducted with this species. Each part of the prostate has its own histology. It is important that each gland is fully represented and correctly defined for the assessment of histopathological criteria. Reliable identification of segments depends on obtaining a section that preserves the anatomical connections of each segment with the others and with the urinary tract. At birth, the prostate is almost fully developed. In contrast, branching morphogenesis occurs postnatally in rats, and lobe-specific branching patterns are completed by 15 to 20 days. In both species, the prostate grows and matures rapidly.

References

1. Roehrborn C. Insights into the relationships between prostatic disorders and their potential impact on future urological practice. *Eur Urol.* 2013;5(Suppl):698–703. [Google Scholar]
2. Cheon DJ, Orsulic S. Mouse models of cancer. *Annu Rev Pathol.* 2011;6:95–119. <http://dx.doi.org/10.1146/annurev.pathol.3.121806.154244>. [PubMed] [Google Scholar]
3. de Jong M, Maina T. Of mice and humans: are they the same?--Implications in cancer translational research. *J Nucl Med.* 2010;51(4):501, 4. <http://dx.doi.org/10.2967/jnumed.109.065706>. [PubMed] [Google Scholar]
4. Maser RS, Choudhury B, Campbell PJ, Feng B, Wong KK, Protopopov A, et al. Chromosomally unstable mouse tumors have genomic alterations similar to various human cancers. *Nature.* 2007;447(7147):966–71. <http://dx.doi.org/10.1038/natur.e05886>. [PMC free article] [PubMed] [Google Scholar]
5. Cunha GR, Donjacour AA, Cooke PS, Mee S, Bigsby RM, Higgins SJ, et al. The endocrinology and developmental biology of the prostate. *Endocr Rev.* 1987;8(3):338–62. <http://dx.doi.org/10.1210/edrv-8-3-338>. [PubMed] [Google Scholar]
6. Karimov Khakimjon Raimberdievich. Optimizing the Effectiveness of Treatment for Injury of the Distal Tendon of the Biceps Braipii Muscle. *International Journal of Integrative and Modern Medicine. IJIMM, Volume 1, Issue 3, 2023.p 52-58*
7. Karimov Hakimjon Rayimberdievich. Sovremennye aspekty lecheniya distalnogo suhozhiliya dvuglavoy myshtsy plecha pri poverjdeniyax. *SCIENTIFIC JOURNAL OF PRACTICAL AND MEDICAL SCIENCES. Volume: 02 Issue: 11 2023. Page 253-258 PRACTICAL*
8. Luke MC, Coffey DS. The male sex accessory tissues. In: Knobil E, Nelly JD, editors. *The Physiology of Reproduction.* New York: Raven Press; 1994. pp. 1435–89. [Google Scholar]
9. Олимова А. З., Шодиев У. М. Репродуктив Ёшдаги эркакларда бепуштлик сабаблари: Бухоро тумани эпидемиологияси //Scientific progress. – 2021. – Т. 2. – №. 7. – С. 499-502.
10. Zokirovna O. A., Abdurasulovich S. B. Ovarian Diseases in Age of Reproductive Women: Dermoid Cyst //IJTIMOIY FANLARDA INNOVASIYA ONLAYN ILMIY JURNALI. – 2021. – Т. 1. – №. 6. – С. 154-161.

11. Olimova A. Z. ECHINOCOCCOSIS OF LIVER OF THREE MONTHLY WHITE RAT //Scientific progress. – 2022. – Т. 3. – №. 3. – С. 462-466.
12. Олимова А. З. Морфологические и морфометрические особенности печени белых беспородных трех месячных крыс после тяжелой черепно-мозговой травмы вызванной экспериментальным путём //BARQARORLIK VA YETAKCHI TADQIQOTLAR ONLAYN ILMIIY JURNALI. – 2021. – Т. 1. – №. 6. – С. 557-563.
13. Oglu M. Z. M., Zokirovna O. A. МОРФОЛОГИЧЕСКИЕ И МОРФОМЕТРИЧЕСКИЕ ПАРАМЕТРЫ ПЕЧЕНИ БЕЛЫХ БЕСПОРОДНЫХ КРЫС, ПЕРЕНЕСШИХ ЭКСПЕРИМЕНТАЛЬНУЮ ЧЕРЕПНО-МОЗГОВУЮ ТРАВМУ ПОСЛЕ МЕДИКАМЕНТОЗНОЙ КОРРЕКЦИИ //JOURNAL OF BIOMEDICINE AND PRACTICE. – 2023. – Т. 8. – №. 1.
14. Олимова А. З., Турдиев М. Р. БУХОРО ШАҲРИДА МЕЪДА ВА ЁН ИККИ БАРМОҚЛИ ИЧАК ЯРАСИ УЧРАШ ЭПИДЕМИОЛОГИЯСИ //Oriental renaissance: Innovative, educational, natural and social sciences. – 2022. – Т. 2. – №. 4. – С. 642-647.
15. Zokirovna O. A. Modern Concepts of Idiopathic Pulmonary Fibrosis //American Journal of Pediatric Medicine and Health Sciences. – 2023. – Т. 1. – №. 3. – С. 97-101.
16. Zokirovna O. A. Pathology of Precancerous Conditions of the Ovaries //American Journal of Pediatric Medicine and Health Sciences. – 2023. – Т. 1. – №. 3. – С. 93-96.
17. Зокировна, Олимова Азиза и Тешаев Шухрат Джумаевич. «Морфологические аспекты печени белых беспородных крыс после тяжелой черепно-мозговой травмы, вызванной экспериментально в виде дорожно-транспортного происшествия». *Scholastic: Journal of Natural and Medical Education* 2.2 (2023): 59-62.
18. Zokirovna O. A. Comparative characteristics of the morphological parameters of the liver at different periods of traumatic brain injury //Euro-Asia Conferences. – 2021. – С. 139-142.
19. Zokirovna O. A. Macroand microscopic structure of the liver of threemonthly white rats //Academic research in educational sciences. – 2021. – Т. 2. – №. 9. – С. 309-312.
20. Олимова А. З. Частота Встречаемости Миомы Матки У Женщин В Репродуктивном Возрасте //BARQARORLIK VA YETAKCHI TADQIQOTLAR ONLAYN ILMIIY JURNALI. – 2021. – Т. 1. – №. 6. – С. 551-556.
21. Zokirovna O. A., Abdurasulovich S. B. Ovarian Diseases in Age of Reproductive Women: Dermoid Cyst //IJTIMOIY FANLARDA INNOVASIYA ONLAYN ILMIIY JURNALI. – 2021. – Т. 1. – №. 6. – С. 154-161.
22. Zokirovna O. A. Cytological screening of cervical diseases: pap test research in the bukhara regional diagnostic center for the period 2015-2019. – 2022.
23. Zokirovna O. A., PREVALENCE R. M. M. EPIDEMIOLOGY OF CANCER OF THE ORAL CAVITY AND THROAT IN THE BUKHARA REGION //Web of Scientist: International Scientific Research Journal. – 2022. – Т. 3. – №. 11. – С. 545-550.

24. Olimova A. Z. The frequency of occurrence of my uterus In women of reproductive age //JOURNAL OF ADVANCED RESEARCH AND STABILITY (JARS). – 2021. – T. 1. – №. 06. – C. 551-556.
25. Olimova Aziza Zokirovna. (2023). MODERN PRINCIPLES OF THE EFFECT OF HEMODIALYSIS THERAPY ON HEART RATE. *International Journal of Integrative and Modern Medicine*, 1(1), 80–85. Retrieved from <http://medicaljournals.eu/index.php/IJIMM/article/view/28>
26. Olimova Aziza Zokirovna. (2023). PATHOMORPHOLOGICAL CHARACTERISTICS OF THE EPIDIDYMIS UNDER IRRADIATION. *International Journal of Integrative and Modern Medicine*, 1(1), 96–100. Retrieved from <http://medicaljournals.eu/index.php/IJIMM/article/view/31>
27. Olimova Aziza Zokirovna. (2023). THE INCIDENCE OF CANCER OF THE ORAL CAVITY AND PHARYNX IN THE BUKHARA REGION. *International Journal of Integrative and Modern Medicine*, 1(1), 86–89. Retrieved from <http://medicaljournals.eu/index.php/IJIMM/article/view/29>
28. Olimova Aziza Zokirovna. (2023). INFLUENCE OF ALCOHOL INTOXICATION ON THE HEART TISSUE OF RATS IN THE EXPERIMENT. *International Journal of Integrative and Modern Medicine*, 1(1), 90–95. Retrieved from <http://medicaljournals.eu/index.php/IJIMM/article/view/30>
29. Olimova Aziza Zokirovna. (2023). Modern Aspects of the Etiology of Gastric Ulcer and Its Complications. *American Journal of Pediatric Medicine and Health Sciences* (2993-2149), 1(3), 163–166. Retrieved from <http://grnjournal.us/index.php/AJPMHS/article/view/208>
30. Zokirovna O. A., Jumaevich T. S. Morphological Aspects of the Liver of White Outbred Rats After Severe Traumatic Brain Injury Caused Experimentally in the Form of a Road Accident //Scholastic: Journal of Natural and Medical Education. – 2023. – T. 2. – №. 2. – C. 59-62.
31. Aziza Zokirovna Olimova GASTRIC ULCER AND ITS COMPLICATIONS // Scientific progress. 2022. №3. URL: <https://cyberleninka.ru/article/n/gastric-ulcer-and-its-complications> (дата обращения: 28.09.2023).
32. Olimova Aziza Zokirovna. (2022). TECHNIQUE FOR CUTTING BIOPSY AND SURGICAL MATERIAL IN THE PRACTICE OF PATHOLOGICAL ANATOMY AND FORENSIC MEDICINE. *Web of Scientist: International Scientific Research Journal*, 3(7), 116–120. <https://doi.org/10.17605/OSF.IO/PSQ59>
33. Zhumayevich N. F., Zokirovna O. A. PATHOMORPHOLOGY OF GASTRIC CANCER //BARQARORLIK VA YETAKCHI TADQIQOTLAR ONLAYN ILMIY JURNALI. – 2022. – C. 330-333.
34. Zokirovna O. A. Epidemiological and Etiological Data of Morphogenesis and Pathomorphology of Congenital Heart Diseases in Children //American Journal of Pediatric Medicine and Health Sciences. – 2023. – T. 1. – №. 4. – C. 88-91.