

Indicators of Physical Development and Anatomical Parameters of the Epididymis of Rats

Namozov Farrukh Zhumayevich
Bukhara State Medical Institute

Abstract: The scientific significance of the results of this research work allows us to expand the level of theoretical knowledge about the histotopography of the epididymis and its structural changes, which is a new approach to understanding the complex mechanism of reproductive processes in the body. In this study, at 90 days of age in white outbred rats, testicular body weight increases by 56.8 times, and body length by 4.8 times. Morphometry of the testicles showed uneven changes in mass, length and thickness in postnatal ontogenesis. Comparison of body mass and length with the mass and size of the testicles shows that as their size increases, body mass increases more than length. Testicular weight increases 1.16 times faster than body weight, and a high rate of testicular growth is reported.

Keywords: indicator, physical development, anatomical parameters, epididymis, rat, morphometry.

Relevance. The volume of the testicles and epididymis, as well as their size, is an important criterion for assessing the male reproductive system, since the efficiency of spermatogenesis is directly related to them. The volume of the testicles in men living in different ecological zones has its own regional and ethnic characteristics. Thus, in the USA, middle-aged men have an average testicular volume of 24.8 cm³, in Japan 17.6 cm³, in Russia - 18.9 + 3.9 cm³. In Uzbekistan, such parameters have not been developed. According to the latest statistical data, the reproductive function of men is sharply deteriorating (D.S. Irgashev et al., 2001; Kh.Ya. Karimov et al., 2003; M.V. Koryakin, 1998; V.S. Paukov, Yu.A. Erokhin, 2001; A. Aktas, O. Pamukcu - Baran, 2005). Just 30-40 years ago, infertility among men of fertile age was 15-25%. Currently, this figure exceeds 40% (V.L. Bykov, 2000; Kh.D. Asadov, 2005). A common cause of infertility in men is impaired spermatogenesis. Thus, in the 60s of the last century, the lower limit of the normal concentration of sperm in 1 ml of seminal fluid was 60 million. In 1983, this figure dropped to 40 million/ml, and in 1992 to 20 million/ml. At the same time, not enough attention is paid to research on the male reproductive system, although it is known that there is a relationship between the efficiency of spermatogenesis and testicular volume.

Being an equal participant in the reproductive process, a man, unlike a woman, is currently subject to higher morbidity and mortality. Accordingly, the life expectancy of men is less than that of women (V.L. Bykov, 2000; Kh.D. Asadov, 2004, 2005; S. Erpek et al., 2005; Ar. Ersay, M. Akkus, et al., 2005). All this suggests that men have problems with reproductive health.

One of the reasons for male infertility is late diagnosis of pathology of the testicles and epididymis. According to literature data (S.A. Allazov, M.A. Fakhratov, 2005; A. Guven, A. Kayikci et al., 2005), 15% of adult men have varicose veins of the spermatic cord (varicocele). Varicocele is observed in 1/3 of all infertile men. At the age of 10 to 25 years, the frequency of

varicocele varies from 9 to 25.8%, and on average is 16.3% (M.V. Koryakin, A.S. Akopyan et al., 1998,2000).

Among other forms of pathology of the male reproductive system, one should mention a sharp (2-4 times) increase in recent decades in the frequency of such developmental anomalies as cryptorchidism (delayed or non-descent of the testicles into the scrotum) and underdevelopment of the penile urethra (hypospadias). In industrialized countries, there is an increase (3-5 times) in the incidence of testicular malignancies. As is known, a factor predisposing to the development of testicular cancer is cryptorchidism. Late detection of cryptorchidism and monorchidism becomes one of the causes of male infertility, untimely treatment of which leads to testicular cancer (S. Irvine, 1996). It remains relevant to study the morphological and morphometric indicators of this organ, especially in postnatal ontogenesis.

Purpose of the study. The purpose of this study is to determine the indicators of physical development and anatomical parameters of the normal epididymis in rats.

Research methods. The experimental study was carried out on material obtained from the testes of 50 outbred rats from birth to 12 months, kept in a vivarium with a 12-hour light cycle, standard nutrition and free access to water. At the beginning of the experiment, all mature rats were placed in a week-long quarantine, and after eliminating somatic or infectious diseases, they were transferred to the usual vivarium regime. Rats were intragastrically injected with 0.5 ml of distilled water using a metal probe for 20 days. Animals were killed in the morning, on an empty stomach, under ether anesthesia by decapitation. After opening the abdominal cavity, the testicles were removed and their weight, length, width, volume and tissue density were examined. The weight of each testicle was measured on an electric scale, and the length and width were measured with a millimeter tape. Testicle size according to the formula:

$V = 0.123 \times n \times c^2$, where: n, c are the length and thickness of the testicle, respectively, and 0.123 is a constant coefficient. The resulting testicles were fixed in Bouin's solution. After passing through high-concentration alcohol, they were embedded in hot paraffin, and then sections of testicular tissue of a standard thickness of 6-7 μm , oriented sagittally or frontally, were prepared. Sections were stained with hematoxylin and eosin according to Van Gieson. The prepared histological preparations were examined under a binocular microscope NLCD-307B (Novel, China). The diameter of the circular sections of the convoluted seminiferous tubules was measured with an eyepiece micrometer DN-107T. The shortest distance between two points located on the opposite diameter and between the basement membrane (inner part) and the germ cells was measured. To estimate the average diameter of convoluted seminiferous tubules, round sections of tubules were selected in different zones of randomly selected sections of the epididymis. Based on the data obtained, the cross-sectional area of the convoluted seminiferous tubules was calculated using the following formula: $S = P \times d^2 / 4$, where: S is the area of an individual part of the seminiferous tubules, d is the diameter of an individual part of the tubule, $P = 3.14$. The state of the spermatogenic epithelium of rats was analyzed using the counting-morphometric method. "spermatogenesis index" (Ukhov Yu.I., Astrakhantsev A.F., 1983). To do this, the entire layer of spermatogenic epithelium is divided into 4 layers: 1 – spermatogonium, 2 – spermatocytes, 3 – spermatids, 4 – spermatozoa. Counting was carried out on 100 sections of tubules, in each of which the safety of these cell layers was determined using a four-point system. To calculate the "Spermatogenesis Index" the following formula is used:

$$I = \sum A : H,$$

where: I is the spermatogenesis index, $\sum A$ is the sum of spermatogenic epithelial layers, N is the number of tubules. In histological preparations, the morphometric parameters of convoluted seminiferous tubules and interstitial Leydig cells were determined, their number in the field of view was counted, and cell sizes were measured. Testicular microvessels were studied. Lumen diameter and wall thickness were measured using a glass micrometer. intrathecal, interlobular and intertubular arterioles, venules and capillaries. The research materials were subjected to statistical processing using parametric and nonparametric analysis methods. Initial data

collection, correction, systematization and visualization of the results were carried out in Microsoft Office Excel 2010 spreadsheets. Statistical analysis IBM SPSS Statistics v. 23 (manufactured by IBM Corporation).

Research results.

Parameters of physical development and anatomical indicators of the epididymis of rats are presented in Table 1.

In newborn rat pups, body weight ranges from 4.2 g to 5.5 g, on average 5.1 ± 0.17 g. Body length (frontal-caudal size) ranges from 3.9 to 4.9 cm, in on average 4.5 ± 0.13 cm. The epididymis is located mainly in the abdominal cavity and in the inguinal-scrotal canal and has a round-oval shape. The mass of the epididymis ranges from 0.012 to 0.023 g, on average 0.02 ± 0.005 g. The length of the epididymis varies from 0.25 to 0.37 cm, on average 0.33 ± 0.016 cm, and its thickness ranges from 0.15 to 0.25 cm, on average 0.22 ± 0.01 cm. The volume of the epididymis ranges from 0.008 to 0.018 cm³, on average 0.013 ± 0.0013 cm³. The tissue density of the epididymis is on average 1.3 g/cm³.

In 16-day-old rat pups in the control group, body weight ranges from 16.3 to 20.1 g, on average 18.7 ± 0.4 g. The absolute increase was 13.6 g, and the growth rate was 266.6%. The body length of the rat pups was 6.3-7.2 cm, on average 6.9 ± 0.10 cm, the absolute increase was 2.4 cm, the growth rate was 53.3%.

The epididymis is located in the abdominal cavity and in the inguinal-scrotal canal and is oval in shape. The weight of the epididymis ranges from 0.09 to 0.15 g, on average 0.11 ± 0.0065 g. The absolute increase was 0.089 g, the growth rate was 430.0%. The length of the epididymis varies from 0.52 to 0.71 cm, on average 0.6 ± 0.02 cm. The absolute growth is 0.27 cm, and the growth rate is 81.8%. The thickness of the epididymis ranges from 0.31 to 0.45 cm, on average it was 0.4 ± 0.01 cm. The absolute increase was 0.18 cm, and the growth rate was 82.0%. The volume of the epididymis is on average 0.068 ± 0.0066 cm³, and the density of the tissue is 1.5 g/cm³.

The body weight of male rats of 30 days of age in the control group ranges from 37 g to 50.5 g, on average 45.1 ± 1.46 g. The absolute increase was 26.4 g, the growth rate was 141.2%. The body length of the rat pups varied from 7.9 to 8.8 cm, on average 8.5 ± 0.09 cm, the absolute increase was 1.6 cm, and the growth rate was 23.2%.

In 30-day-old rats of the control group, the epididymis are located in the inguinal-scrotal canal and in the scrotum, have an oval shape, the thickness of the oval is equal to 2/3 of the length of the epididymis. The weight of the epididymis ranges from 0.15 to 0.25 g, on average 0.21 ± 0.011 g. The absolute increase was 0.11 g, the growth rate was 100%. The length of the epididymis varies from 0.65 to 0.80 cm, on average 0.74 ± 0.016 cm, the absolute increase was 0.14 cm, the growth rate was 3.3%. The thickness of the epididymis varies between 0.4-0.55 cm, on average 0.49 ± 0.016 cm, the absolute increase is 0.09 cm, the growth rate is 22.5%. The volume of the epididymis individually is on average 0.13 ± 0.009 cm³, and the tissue density is 1.6 g/cm³.

In 46-day-old rats of the control group, body weight ranges from 47.5 g to 60.1 g, on average 53.01 ± 0.65 g. The growth rate is 17.5%, the absolute increase is 7.9 g. The body length is from 8.5 to 9.4 cm, on average 9.1 ± 0.08 cm. Absolute growth - 0.6 cm, growth rate - 7.1%. Both epididymis are oval in shape; no difference in size or weight was found. The weight of the epididymis ranges from 0.25 to 0.41 g, on average 0.32 ± 0.015 g, the absolute increase was 0.11 g, the growth rate is 55.6%. The length of the epididymis ranges from 0.7 to 0.9 cm, on average 0.85 ± 0.018 cm, the absolute increase is 0.11 cm, the growth rate is 7.8%. The thickness ranges from 0.45 to 0.6 cm, on average 0.57 ± 0.009 cm. The growth rate is 7.1%, and the absolute increase is 0.08 cm. The volume of the epididymis is on average 0.2 ± 0.01 cm³. The average density of the epididymis is 1.64 g/cm³.

In 60-day-old male rats of the control group, body weight ranges from 59.8 to 75.32 g, with an average of 69.5 ± 1.43 g. The growth rate is 31.1%, the absolute increase is 16.5 g. Body length

varies from 9.9 to 11.1 cm, on average 10.7 ± 0.11 cm. The growth rate is 17.6%, and the absolute increase is 1.6 cm.

The epididymis is oval in shape and is located in most cases in the scrotum, sometimes in the inguinoscrotal canal. The body weight of the epididymis ranges from 0.35 to 0.5 g, on average - 0.43 ± 0.015 g, the absolute increase is 0.1 g, and the growth rate is 29.9%. The length of the epididymis varies from 0.8 to 1.0 cm, on average - 0.93 ± 0.020 cm, the absolute increase is 0.12 cm, and the growth rate is 9.4%. The thickness of the epididymis ranges from 0.5 to 0.65 cm, on average - 0.61 ± 0.015 cm. The growth rate is 7.0%, the absolute increase is 0.04 cm. The volume of the epididymis is on average 0.25 ± 0.012 cm³, density 1.7 g/cm³.

In 76-day-old male rats of the control group, body weight ranges from 71.0 to 83.5 g, on average 75.4 ± 1.35 g. The growth rate is 8.5%, the absolute increase is 5.9 g. Length the body ranges from 10.6 to 14.2 cm, on average 12.5 ± 0.39 cm, the growth rate is 16.8%, the absolute increase is 1.8 cm (Fig. 1).

The epididymis are oval in shape, their weight ranges from 0.4 to 0.6 g, on average 0.56 ± 0.02 g. The rate of increase in the mass of the epididymis is 31.0%. The length of the epididymis ranges from 0.8 to 1.1 cm, on average - 0.98 ± 0.032 cm. The growth rate is 5.3%, and the absolute increase is 0.005 cm. The thickness of the epididymis ranges from 0.6 to 0.7 cm, on average - 0.65 ± 0.011 cm, absolute growth - 0.04 cm, and the growth rate is 6.5%. The volume of the epididymis individually is 0.15 - 0.3 cm³, on average - 0.29 ± 0.0162 cm³, absolute increase - 0.044 cm³. The growth rate is 17.6%. The tissue density of the epididymis is 1.8 g/cm³.

In male rats of 90 days of age in the control group, body weight ranges from 91.5 to 112.0 g, on average - 101.4 ± 2.05 g. The absolute increase was 26.0 g, the growth rate was 35.5%. Body length ranges from 12.7 to 16.1 cm, with an average of 14.6 ± 0.34 cm. The growth rate is 15.9%. The absolute increase is 2.1 cm. The epididymis is oval in shape and is located in the scrotum, less often in the inguinal-scrotal canal (Fig. 2).

The mass of the epididymis varies individually from 0.6 g to 0.85 g, on average - 0.76 ± 0.025 g. The growth rate is 36.4%, and the absolute increase is 0.2 g. The length of the epididymis is 1.2 - 1.6 cm, on average - 1.30 ± 0.04 cm. Growth rate - 32.7%, absolute growth - 0.32 cm. The thickness of the epididymis ranges from 0.7 to 1.5 cm, on average - 0.9 ± 0.08 cm. The growth rate is 38.5%, the absolute growth is 0.25 cm. The volume of the epididymis individually ranges from 0.6 to 0.8 cm³, on average - 0.64 ± 0.02 cm³. The volume of the epididymis increased by 2.2 times compared to the previous age, the growth rate was 117.7%. The absolute increase was 0.346 cm³. The tissue density of the epididymis at this age decreases to 1.18 g/cm³. As microscopic examination of sections of tissue of the epididymis shows, at this age the diameter of the convoluted seminiferous tubules increases, a free lumen appears for the advancement of mature sperm, therefore the density of the tissue of the epididymis sharply decreases.

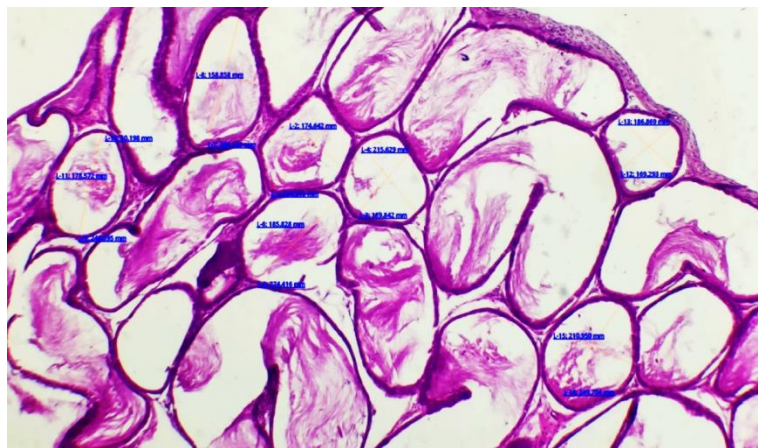

Fig. 1. Testicles of 76-day-old rats. 1-convoluted bundles of spermatozoites; 2-channel space. Hematoxylin-eosin staining. Ob. 10 x ok. 20

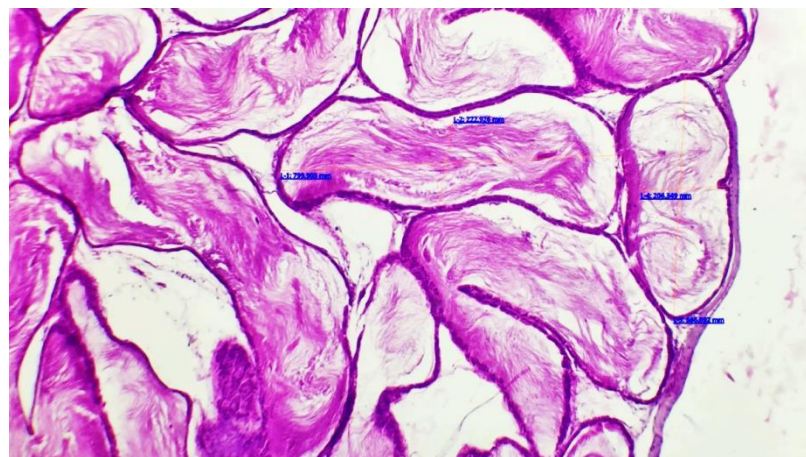


Fig. 2. Testes of 90-day-old rats. 1-convoluted seminiferous tubules; 2- interchannel space. Hematoxylin-eosin staining. Ob. 10 x ok. 20

Table 1. Parameters of physical development and anatomical indicators of the epididymis of rats

Age Day	Body weight, (g)	Body length, cm	Weight of the epididymis, g	Length of epididymis, cm	Epididymal thickness, cm	Volume of epididymis, cm ³	Density of epididymal tissue, g/cm ³
Newborns	5,1±0,17	4,5±0,13	0,017±0,0015	0,33 ±0,016	0,22±0,010	0,013±0,0013	1,3
16	18,7±0,4	6,9±0,10	0,116±0,006	0,60±0,020	0,40±0,015	0,068±0,007	1,5
30	45,1±1,46	8,5±0,09	0,21±0,011	0,74±0,016	0,49±0,016	0,13±0,009	1,6
46	53±0,65	9,1±0,08	0,32±0,015	0,85±0,018	0,57±0,014	0,20±0,01	1,64
60	69,5±1,43	10,7±0,11	0,43±0,015	0,93±0,020	0,61±0,015	0,25±0,01	1,7
76	75,4±1,35	12,5±0,39	0,56±0,020	0,98±0,032	0,65±0,011	0,29±0,016	1,8
90	101,4±2,05	14,6±0,34	0,76±0,025	1,3±0,04	0,9 ±0,08	0,64±0,02	1,18

Conclusions. In the study, in adulthood (90 days) body weight increases by 56.8 times, and body length by 4.8 times. Morphometry of the testicles showed uneven changes in mass, length and thickness in postnatal ontogenesis. Comparison of body mass and length with the mass and size of the testicles shows that as their size increases, body mass increases more than length. Testicular weight increases 1.16 times faster than body weight, and a high rate of testicular growth is reported. The study of the macroscopic and microscopic structure of the testicle at different ages serves to timely identify reproductive problems through comparison. The information obtained allows us to assess the level of changes occurring in pathologies of the reproductive system and make an early diagnosis. The original results of this scientific research can be recommended as additional lecture material when giving lectures on anatomy, histology and other morphological sciences.

Literature

1. Djumayevich N. F. Macro-Microscopic Anatomy and Reactive Changes in the Testimonial Appendices under Exposure to Magnesium Chlorate in Postnatal Ontogenesis //International Journal of Innovative Analyses and Emerging Technology. – 2021. – T. 1. – №. 6. – C. 152-155.
2. Jumaevich N. F. Comparative characteristics of testicular appendages in normal conditions and when exposed to a biostimulator against the background of radiation sickness //International journal for innovative engineering and management research. – 2021. – C. 28-30.
3. Samiyevich S. E., INTERVENTIONS N. F. J. E. OZONE THERAPY IN THE COMPLEX TREATMENT OF PATIENTS WITH MECHANICAL JAUNDICE AND CHOLANGITIS WITH CHOLEDOCHOLITHIASIS //ResearchJet Journal of Analysis and Inventions. – 2021. – T. 9. – №. 2. – C. 22-27.

4. Турдиев М. Р., Махмудова Г. Ф. Морфофункциональные изменения, происходящие в селезенке в результате действия внешних и внутренних факторов //Тиббиётда янги кун. – 2022. – №. 11. – С. 49.
5. Turdiyev M. R., Sokhibova Z. R. Morphometric characteristics of the Spleen of white rats in normal and in chronic Radiation Disease //The american journal of medical sciences and pharmaceutical research. – 2021. – Т. 3. – №. 02. – С. 146-154.
6. Turdiyev M. R., Teshayev S. J. Comparative characteristics of the spleen of white rats in normal and chronic radiation sickness //Chief Editor. – Т. 7. – №. 11.
7. Turdiyev M. R. Teshayev Sh //J. Morphometric Assessment of Functional Immunomorphology of White Rat Spleen in the Age Aspect American Journal of Medicine and Medical Sciences. – 2019. – Т. 9. – №. 12. – С. 523-526.
8. Турдиев М. Р. и др. ЧАСТОТА РАСПРОСТРАНЕНИЯ РАКА МОЛОЧНОЙ ЖЕЛЕЗЫ В БУХАРСКОЙ ОБЛАСТИ //Молодежный инновационный вестник. – 2015. – Т. 4. – №. 1. – С. 267-268.
9. Turdiyev M. R. Teshayev Sh. J. Comparative characteristics of the morphological and morphometric parameters of the spleen of white rats in normal conditions, chronic radiation sickness and correction with a biostimulant //Problems of biology and Medicine. – 2020. – №. 4. – С. 120.
10. Турдиев М. Р., Сохибова З. Р. Этиологические факторы острых аллергических состояний у детей, проживающих в условиях города Бухары //Новый день в медицине. – 2018. – №. 3. – С. 23.
11. Турдиев М. Р. Морфофункциональные особенности селезенки белых крыс в норме и при хронической лучевой болезни //Новый день в медицине.–2020.–3 (31)–С. – С. 734-737.
12. Turdiyev M. R., Sanoyev B. A. Pathologi of the afterbirth during 2020 in the Bukhara regional perinatal center //Eurasian Journal of Medical and Natural sciences. Volume1. – 2021. – №. 2.
13. Turdiyev M. R. et al. ChASTOTA RASPROSTRANENIYa RAKA MOLOChNOY ZhELEZY V BUKhARSKOY OBLASTI //Молодежный инновационный вестник. – 2015. – Т. 4. – №. 1. – С. 267-268.
14. Turdiyev M. R. Morphological and morphometric parameters of lymphoid Structures of the Spleen of white rats in Postnatal ontogenesis in Dynamics of Age. European multidisciplinary journal of modern science. Volume 4, 2022. – P-319-326.
15. Turdiyev M. R. Morphological and Orthometric Parameters of lymphoid Structures of the Spleen of white rats //Central Asian Journal of Medical and Natural Sciences. Volume. – Т. 2.
16. Turdiyev M. R. Morphometric Indicators of Morphological Structures of the White Rats Spleen in Postnatal Ontogenesis //Web of Synergy: International Interdisciplinary Research Journal. – 2023. – Т. 2. – №. 4. – С. 576-580.
17. Turdiyev M. R., Boboeva R. R. CHOLERETIC ACTIVITY OF RUTANA AT THERAPEUTIC APPLICATION IN RATS WITH HELIOTRIN HEPATITIS //Oriental renaissance: Innovative, educational, natural and social sciences. – 2021. – Т. 1. – №. 8. – С. 644-653.
18. Турдиев М. Р. Морфофункциональные Изменения Лимфоидных Структур Селезенки Белых Крыс В Постнатальном Онтогенезе В Динамике Возраста //AMALIY VA TIBBIYOT FANLARI ILMIY JURNALI. – 2023. – Т. 2. – №. 5. – С. 188-192.

19. Turdiev M. R. Morphofunctional Changes in Lymphoid Structures of the Spleen of White Rats in Postnatal Ontogenesis in the Dynamics of Age //Web of Synergy: International Interdisciplinary Research Journal. – 2023. – Т. 2. – №. 5. – С. 144-148.
20. Rustamovich T. M. et al. Edematous Breast Cancer Problems of Diagnosis and Treatment //Research Journal of Trauma and Disability Studies. – 2022. – Т. 1. – №. 10. – С. 93-100.
21. Turdiev M. R. Histological Analysis of the Spleen of White Rats in Postnatal Ontogenesis //Research Journal of Trauma and Disability Studies. – 2022. – Т. 1. – №. 10. – С. 135-141.
22. Rustamovich T. M. Morphological and Orthometric Parameters of Lymphoid Structures of the Spleen of White Rats //Central Asian Journal of Medical and Natural Science. – 2021. – Т. 2. – №. 5. – С. 122-128.
23. Олимова А. З., Шодиев У. М. Репродуктив Ёшдаги эркакларда бепуштлик сабаблари: Бухоро тумани эпидемиологияси //Scientific progress. – 2021. – Т. 2. – №. 7. – С. 499-502.
24. Zokirovna O. A., Abdurasulovich S. B. Ovarian Diseases in Age of Reproductive Women: Dermoid Cyst //IJTIMOIY FANLARDA INNOVASIYA ONLAYN ILMIY JURNALI. – 2021. – Т. 1. – №. 6. – С. 154-161.
25. Olimova A. Z. ECHINOCOCCOSIS OF LIVER OF THREE MONTHLY WHITE RAT //Scientific progress. – 2022. – Т. 3. – №. 3. – С. 462-466.
26. Олимова А. З. Морфологические и морфометрические особенности печени белых беспородных трех месячных крыс после тяжелой черепно-мозговой травмы вызванной экспериментальным путём //BARQARORLIK VA YETAKCHI TADQIQOTLAR ONLAYN ILMIY JURNALI. – 2021. – Т. 1. – №. 6. – С. 557-563.
27. Oglu M. Z. M., Zokirovna O. A. МОРФОЛОГИЧЕСКИЕ И МОРФОМЕТРИЧЕСКИЕ ПАРАМЕТРЫ ПЕЧЕНИ БЕЛЫХ БЕСПОРОДНЫХ КРЫС, ПЕРЕНЕСШИХ ЭКСПЕРИМЕНТАЛЬНУЮ ЧЕРЕПНО-МОЗГОВУЮ ТРАВМУ ПОСЛЕ МЕДИКАМЕНТОЗНОЙ КОРРЕКЦИИ //JOURNAL OF BIOMEDICINE AND PRACTICE. – 2023. – Т. 8. – №. 1.
28. Олимова А. З., Турдиев М. Р. БУХОРО ШАХРИДА МЕЪДА ВА ЁН ИККИ БАРМОҚЛИ ИЧАК ЯРАСИ УЧРАШ ЭПИДЕМИОЛОГИЯСИ //Oriental renaissance: Innovative, educational, natural and social sciences. – 2022. – Т. 2. – №. 4. – С. 642-647.
29. Zokirovna O. A. Modern Concepts of Idiopathic Pulmonary Fibrosis //American Journal of Pediatric Medicine and Health Sciences. – 2023. – Т. 1. – №. 3. – С. 97-101.
30. Zokirovna O. A. Pathology of Precancerous Conditions of the Ovaries //American Journal of Pediatric Medicine and Health Sciences. – 2023. – Т. 1. – №. 3. – С. 93-96.
31. Зокировна, Олимова Азиза и Тешаев Шухрат Джумаевич. «Морфологические аспекты печени белых беспородных крыс после тяжелой черепно-мозговой травмы, вызванной экспериментально в виде дорожно-транспортного происшествия». *Scholastic: Journal of Natural and Medical Education* 2.2 (2023): 59-62.
32. Zokirovna O. A. Comparative characteristics of the morphological parameters of the liver at different periods of traumatic brain injury //Euro-Asia Conferences. – 2021. – С. 139-142.
33. Zokirovna O. A. Macroand microscopic structure of the liver of threemonthly white rats //Academic research in educational sciences. – 2021. – Т. 2. – №. 9. – С. 309-312.
34. Олимова А. З. Частота Встречаемости Миомы Матки У Женщин В Репродуктивном Возрасте //BARQARORLIK VA YETAKCHI TADQIQOTLAR ONLAYN ILMIY JURNALI. – 2021. – Т. 1. – №. 6. – С. 551-556.

35. Zokirovna O. A., Abdurasulovich S. B. Ovarian Diseases in Age of Reproductive Women: Dermoid Cyst //IJTIMOIY FANLARDA INNOVASIYA ONLAYN ILMIY JURNALI. – 2021. – T. 1. – №. 6. – C. 154-161.
36. Zokirovna O. A. Cytological screening of cervical diseases: pap test research in the bukhara regional diagnostic center for the period 2015-2019. – 2022.
37. Zokirovna O. A., PREVALENCE R. M. M. EPIDEMIOLOGY OF CANCER OF THE ORAL CAVITY AND THROAT IN THE BUKHARA REGION //Web of Scientist: International Scientific Research Journal. – 2022. – T. 3. – №. 11. – C. 545-550.
38. Olimova A. Z. The frequency of occurrence of my uterus In women of reproductive age //JOURNAL OF ADVANCED RESEARCH AND STABILITY (JARS). – 2021. – T. 1. – №. 06. – C. 551-556.
39. Olimova Aziza Zokirovna. (2023). MODERN PRINCIPLES OF THE EFFECT OF HEMODIALYSIS THERAPY ON HEART RATE. *International Journal of Integrative and Modern Medicine*, 1(1), 80–85. Retrieved from <http://medicaljournals.eu/index.php/IJIMM/article/view/28>
40. Olimova Aziza Zokirovna. (2023). PATHOMORPHOLOGICAL CHARACTERISTICS OF THE EPIDIDYMISS UNDER IRRADIATION. *International Journal of Integrative and Modern Medicine*, 1(1), 96–100. Retrieved from <http://medicaljournals.eu/index.php/IJIMM/article/view/31>
41. Olimova Aziza Zokirovna. (2023). THE INCIDENCE OF CANCER OF THE ORAL CAVITY AND PHARYNX IN THE BUKHARA REGION. *International Journal of Integrative and Modern Medicine*, 1(1), 86–89. Retrieved from <http://medicaljournals.eu/index.php/IJIMM/article/view/29>
42. Olimova Aziza Zokirovna. (2023). INFLUENCE OF ALCOHOL INTOXICATION ON THE HEART TISSUE OF RATS IN THE EXPERIMENT. *International Journal of Integrative and Modern Medicine*, 1(1), 90–95. Retrieved from <http://medicaljournals.eu/index.php/IJIMM/article/view/30>
43. Olimova Aziza Zokirovna. (2023). Modern Aspects of the Etiology of Gastric Ulcer and Its Complications. *American Journal of Pediatric Medicine and Health Sciences (2993-2149)*, 1(3), 163–166. Retrieved from <http://grnjournal.us/index.php/AJPMHS/article/view/208>
44. Zokirovna O. A., Jumaevich T. S. Morphological Aspects of the Liver of White Outbred Rats After Severe Traumatic Brain Injury Caused Experimentally in the Form of a Road Accident //Scholastic: Journal of Natural and Medical Education. – 2023. – T. 2. – №. 2. – C. 59-62.
45. Aziza Zokirovna Olimova GASTRIC ULCER AND ITS COMPLICATIONS // Scientific progress. 2022. №3. URL: <https://cyberleninka.ru/article/n/gastric-ulcer-and-its-complications> (дата обращения: 28.09.2023).
46. Olimova Aziza Zokirovna. (2022). TECHNIQUE FOR CUTTING BIOPSY AND SURGICAL MATERIAL IN THE PRACTICE OF PATHOLOGICAL ANATOMY AND FORENSIC MEDICINE. *Web of Scientist: International Scientific Research Journal*, 3(7), 116–120. <https://doi.org/10.17605/OSF.IO/PSQ59>
47. Zhumayevich N. F., Zokirovna O. A. PATHOMORPHOLOGY OF GASTRIC CANCER //BARQARORLIK VA YETAKCHI TADQIQOTLAR ONLAYN ILMIY JURNALI. – 2022. – C. 330-333.
48. Zokirovna O. A. Epidemiological and Etiological Data of Morphogenesis and Pathomorphology of Congenital Heart Diseases in Children //American Journal of Pediatric Medicine and Health Sciences. – 2023. – T. 1. – №. 4. – C. 88-91.